

PediatricsⁱⁿReview[®]

Consultation with the Specialist: Pediatric Approach to Craniosynostosis

Gregory S. Liptak and Joseph M. Serletti

Pediatrics in Review 1998;19;352

DOI: 10.1542/pir.19-10-352

The online version of this article, along with updated information and services, is located on the World Wide Web at:

<http://pedsinreview.aappublications.org/content/19/10/352>

An erratum has been published regarding this article. Please see the attached page for:

<http://pedsinreview.aappublications.org/http://pedsinreview.aappublications.org/content/20/1/20.full.pdf>

Pediatrics in Review is the official journal of the American Academy of Pediatrics. A monthly publication, it has been published continuously since 1979. Pediatrics in Review is owned, published, and trademarked by the American Academy of Pediatrics, 141 Northwest Point Boulevard, Elk Grove Village, Illinois, 60007. Copyright © 1998 by the American Academy of Pediatrics. All rights reserved. Print ISSN: 0191-9601.

American Academy of Pediatrics

DEDICATED TO THE HEALTH OF ALL CHILDREN™



Pediatric Approach to Craniosynostosis

Gregory S. Liptak, MD, MPH* and Joseph M. Serletti, MD†

Occurrence

Asymmetry of the head is a common occurrence in infants and may have a number of etiologies, including positional deformity, simple craniosynostosis, complex craniofacial synostosis, metabolic bone disease, depressed skull fracture, microcephaly due to brain damage, and hydrocephalus. Deformations of the head attributable to prenatal compression usually resolve by the time a child is 2 months of age. However, a number of centers have reported a recent increase in the occurrence of cranial deformations in infants older than 6 months, which is attributed to the current recommendation that children sleep on their backs to avoid sudden infant death syndrome.

Synostosis of a single suture may lead to only cosmetic changes, but synostosis of several sutures may be life-threatening and lead to increased intracranial pressure, loss of vision, and severe deformities that affect social interactions. Primary craniosynostosis, which is defined as synostosis without an underlying abnormality of the brain or metabolic defect, occurs in 1 in 2,000 births. Secondary craniosynostosis, such as would be due to cerebral atrophy, is somewhat less common. Figure 1 shows the occurrence of isolated craniosynostosis in a referral center. ("Isolated" in this context means involvement of the sutures only without an identified genetic or chromosomal abnormality such as Apert syndrome.) Involvement of the sagittal suture is the most common form and occurs more fre-

quently in males than in females.

Synostosis of a single suture is more common than synostosis of multiple sutures.

Etiology

Secondary craniosynostosis may be due to a structural cerebral abnormality such as atrophy or hypoplasia and may be related to other conditions such as hyperthyroidism, severe anemia (eg, thalassemia), or a metabolic condition (eg, mucopolysaccharidosis). Primary craniosynostosis has been related to intrauterine constraint, such as occurs with twinning or with uterine abnormalities such as a bicornuate uterus. Exposure to maternal smoking or high altitude during gestation has been associated with an increased occurrence of craniosynostosis. Genetic abnormalities such as Apert syndrome and chromosomal anomalies such as abnormalities of chromosome 13q can cause craniosynostosis. Some occurrences of isolated craniosynostosis are familial (eg, involvement of both coronal sutures), but most cases do not have a clear etiology.

A number of discrete genetic conditions produce craniosynostosis, such as Crouzon syndrome (Fig. 2). One of the most exciting developments in the understanding of craniosynostosis has come through the discovery that at least four genetic syndromes associated with craniosynostosis (Table 1) are related to abnormalities of fibroblast growth factor receptor 2. In fact, all four of the syndromes shown in Table 1, which are autosomal dominant, have abnormalities of the same region of chromosome 10, despite having significant differences in phenotype. Although

these entities account for only 5% of children who have craniosynostosis, this knowledge may increase the understanding of other types of craniosynostosis as well as the role of fibroblast growth factors and may lead to interventions to prevent or ameliorate the effects of these genetic anomalies.

Growth of the Skull

Cranial growth occurs as a direct result of the growing brain. If all cranial sutures are open, the brain grows normally without areas of restriction, and skull growth and shape occur normally. Without adequate stimulation from the brain and other intracranial soft tissues, the skull will not grow normally. For example, an infant who has severe cerebral atrophy will develop microcephaly and premature closure of all sutures because of the lack of stimulation of the growing brain upon the surrounding skull.

Once a suture becomes fused, growth perpendicular to that suture becomes restricted, and the fused bones act as a single bony structure. With failure of growth across a single fused suture, compensatory growth occurs at the remaining open sutures to accommodate the growing brain. These compensatory changes allow continued unrestricted brain growth without the development of increased intracranial pressure in most instances. This combination of restricted perpendicular growth and compensatory changes produces the typical deformities seen with each type of single suture synostosis. In scaphocephaly, for instance, there is no growth perpendicular to the sagittal suture, which results in bitemporal narrowing. Compensatory changes cause

*Associate Professor of Pediatrics.

†Associate Professor of Surgery, University of Rochester Medical Center, Rochester, NY.

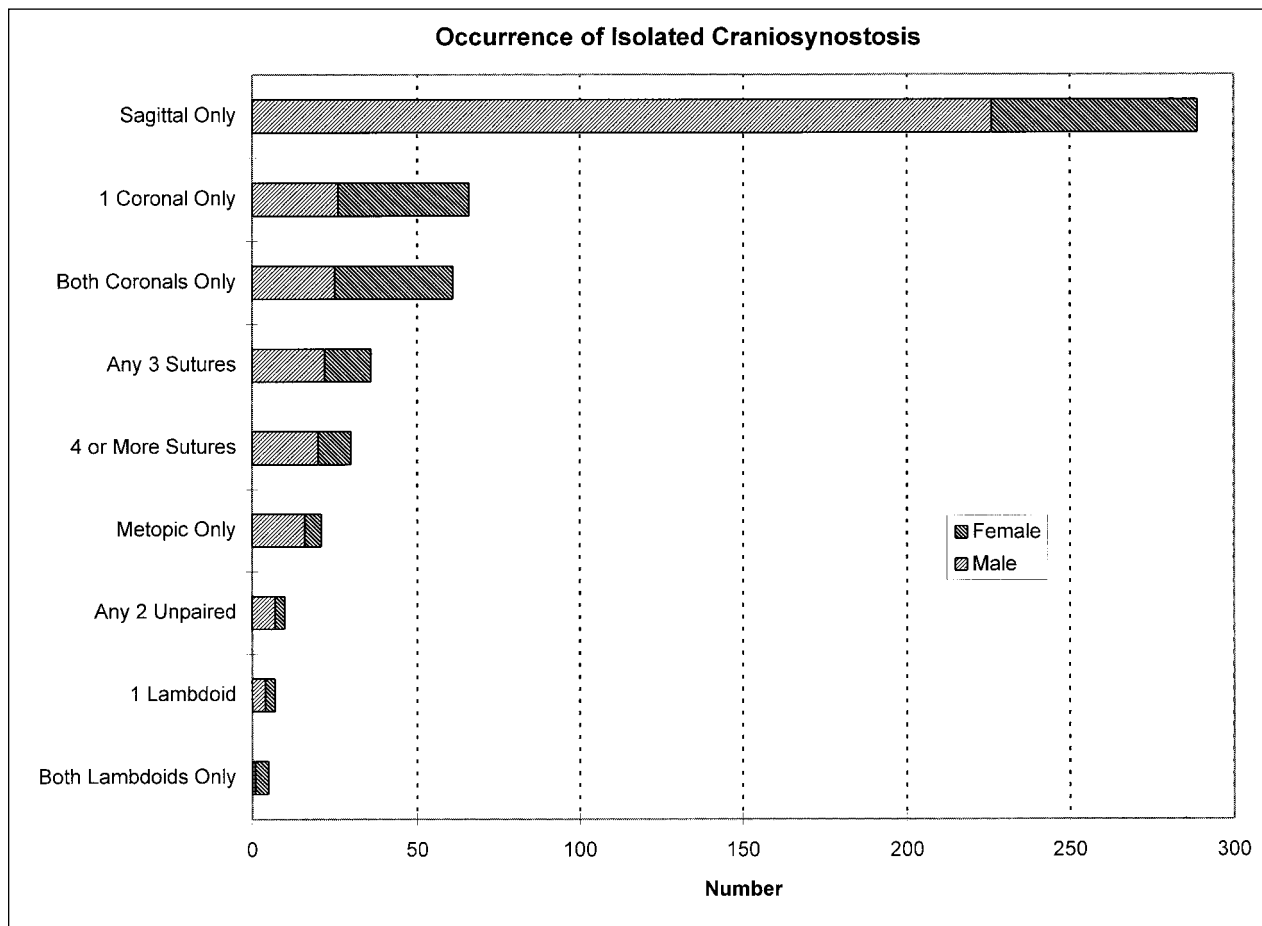


FIGURE 1. Occurrence of isolated craniosynostosis in a referral center. Reprinted with permission from Shillito J Jr, Matson DD. Craniosynostosis: a review of 519 surgical patients. *Pediatrics*. 1968;41:829-853.



FIGURE 2. Mother and child who both have Crouzon syndrome.

cranial elongation in the anterior-posterior direction. In plagiocephaly, the absence of growth across one coronal suture results in retrusion of the forehead and upper orbit. Compensatory changes occur with protrusion or overgrowth of the

ipsilateral occiput and contralateral frontal bone.

Complex, multiple sutural synostosis frequently extends to premature fusion of the sutures of the base of the skull, leading to midfacial hypoplasia. Midfacial hypoplasia, as seen in children who have Apert syndrome, is characterized by shallow orbits, a foreshortened nasal dorsum, maxillary retrognathia, and occasionally upper airway obstruction.

Evaluation of the Child

A child who presents with an asymmetric head should receive a thorough physical examination to identify deformations or malformations of other organ systems (Fig. 3). The range of motion of the neck should be evaluated because torticollis that is present at birth can, if not treated, lead to persistent asymmetry of the head and face. Torticollis can be managed with physical therapy, which should improve the range of

cervical rotation as well as the position and shape of the head in most cases. If this does not occur, surgery to release the sternocleidomastoid muscle may be indicated. Examination of the extremities and back of a child who has an asymmetric head may reveal syndactyly or deformations such as congenital dislocation of the hip, scoliosis, and deformed feet, which are more common among children who have deformations of the head.

The craniofacial region should be evaluated by viewing the child from the front, side (profile), back, below the chin (worm's eye view), and above the head (bird's eye view). Abnormalities, such as the orbital asymmetry of a child who has plagiocephaly, can be visualized easily in the bird's eye view (Fig 4).

A complete history, including family history of craniofacial abnormalities, should be obtained. The symmetry, proportionality, and balance of the facial structures, includ-

TABLE 1. Autosomal Dominant Genetic Syndromes Associated With Abnormalities of Fibroblast Growth Factor Receptor 2 (FGFR2)

| CONDITION | LOCATION OF ABNORMALITY (CHROMOSOME/GENE) | PRIMARY CHARACTERISTICS |
|---|---|--|
| Apert syndrome (Acrocephalosyndactyly, type I) | 10q25.3-q26/FGFR2 Exon 7(U) | Acrocephaly, brachycephaly, flat face, large fontanelle, shallow orbits, hypertelorism, down-slanting palpebral fissures, maxillary hypoplasia, narrow palate, syndactyly, short fingers, broad thumbs and great toes, fusion of cervical vertebrae, mental retardation (in 50%), acne |
| Crouzon syndrome (Craniofacial dysostosis) | 10q25.3-q26/FGFR2 Exon 9(B) | Shallow orbits, hypertelorism, frontal bossing, maxillary hypoplasia, curved beak-shaped nose, A-shaped palate, conductive hearing loss |
| Jackson-Weiss syndrome (Cephalo-syndactyly) | 10q25.3-q26/FGFR2 Exon 9(B) | Shallow orbits, hypertelorism, mid-facial hypoplasia, syndactyly, broad great toe |
| Pfeiffer syndrome (Acrocephalosyndactyly, type V) | 10q25.3-q26/FGFR2 Exon 9(B) and 8p11.2-p12/FGFR1 Exon 5 | Brachycephaly, full high forehead, hypertelorism, up-slanting palpebral fissures, small nose, broad thumbs and great toes, syndactyly |

ing the nose, ears, and eyebrows, which constitute the “aesthetics” of the face and skull, should be evaluated. A systematic approach that enables thorough evaluation involves separating the face and skull into regions and evaluating each region separately. These regions are: 1) the forehead and upper orbit, 2) the orbito-naso-zygomatic area, 3) the maxillomandibular area, and 4) the posterior cranial vault.

The physical examination can suggest whether craniosynostosis is present. This is sometimes obvious from the shape of the skull. Certain skull shapes are characteristic for their affected suture. For example, a keel-shape deformity of the central forehead indicates trigonocephaly or metopic synostosis (Fig. 5a); a flattened occipital area may indicate premature closure of the lambdoidal sutures (Fig. 5b); a long, narrow cranium suggests scaphocephaly or sagittal synostosis (Fig. 5c); and a unilaterally recessed forehead and upper orbit suggests plagiocephaly or unilateral coronal synostosis (Fig. 5d).

The presence of a palpable bony ridge in the location of a cranial suture strongly suggests synostosis. If computed tomography (CT) is not

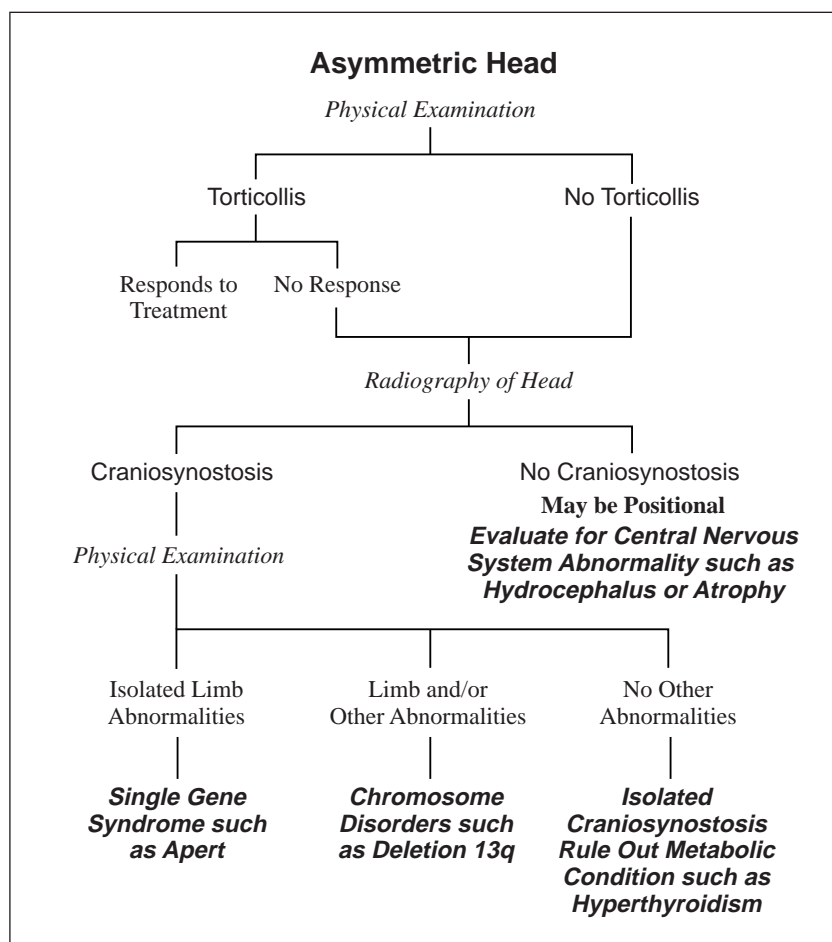


FIGURE 3. Flow diagram for evaluation of a child who has an asymmetric head.

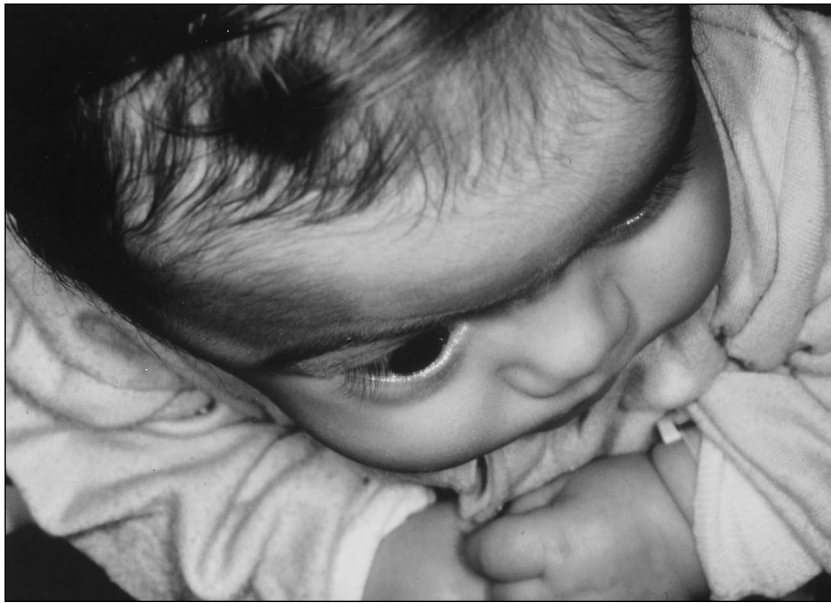

FIGURE 4. "Bird's eye" view of a child who has plagiocephaly, illustrating orbital asymmetry.

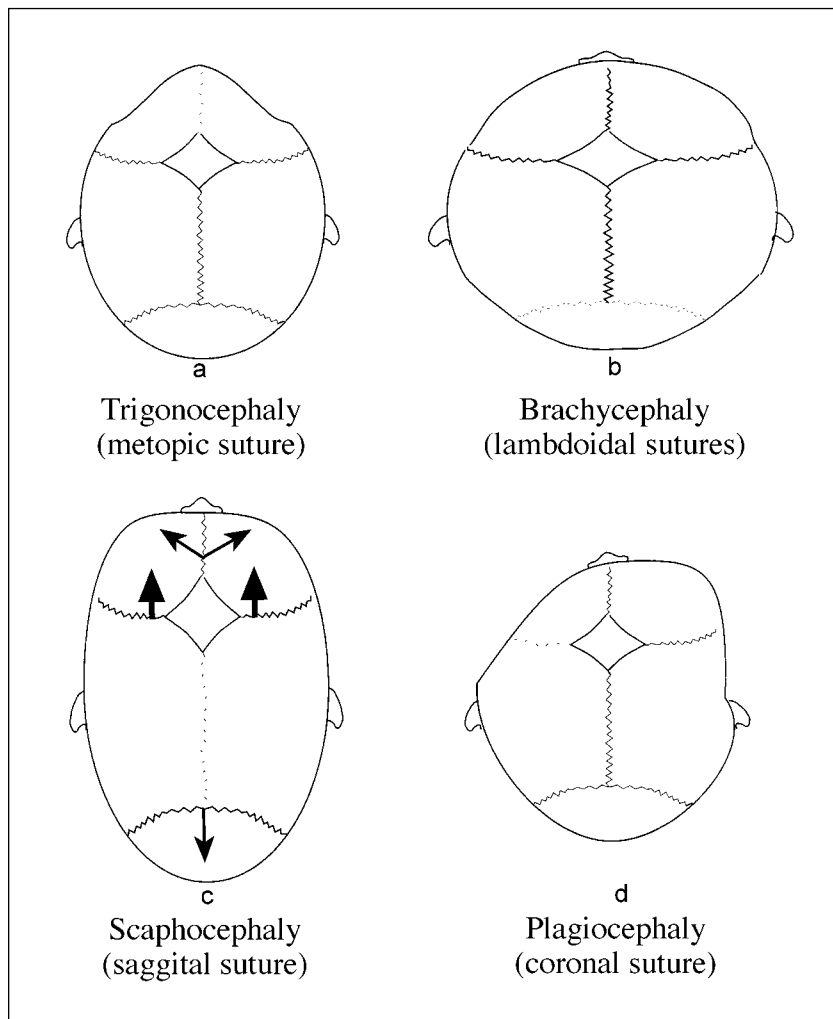


FIGURE 5. Four categories of craniosynostosis and the sutures involved. Plagiocephaly may result from synostosis of the lambdoidal as well as the coronal suture. Figure 5C demonstrates the forces that cause the skull to grow abnormally.

readily available and the diagnosis cannot be ascertained by physical examination, plain radiographs of the skull may be helpful. Abnormalities seen on radiography include sclerosis of the suture line, bony bridging and beaking or heaping up of bone along the suture line, or indistinctness of the suture. These abnormalities may involve only a small part of the suture line and require a thorough search. The entire suture line may not be visible on a single film, resulting in a falsely negative interpretation. Infants whose suture lines are primarily cartilaginous may have no apparent abnormalities on radiography, but distinctive abnormalities in the shape of the skull can be identified on the films. CT scanning with three-dimensional reconstruction has become the most useful radiologic examination in identifying the skull shape and the presence or absence of involved sutures (Fig. 6). If there is concern about the anatomy or structure of the cerebrum, magnetic resonance imaging may be helpful. If indicated, chromosome analysis or referral to a geneticist may help to determine the underlying cause of the craniosynostosis.

Differentiating Lambdoidal Synostosis from Positional Deformation in Plagiocephaly

Differentiating positional from structural changes is important for determining the treatment and prognosis for a child who presents with posterior plagiocephaly. There is controversy over whether prolonged positional changes can lead to physical changes in the lambdoidal sutures, called "functional synostosis." First, true synostosis of the lambdoidal suture is rare, whereas positional deformity of the skull is becoming increasingly common. Second, children who have lambdoidal synostosis usually have distinctive features, including: 1) a palpable ridge over the suture line, 2) an ipsilateral occipitomastoid bulge, 3) posterior displacement of the ipsilateral ear (in positional deformities, the ipsilateral ear is displaced anteriorly), 4) tilt in the base of the skull when viewed from the back of the child's

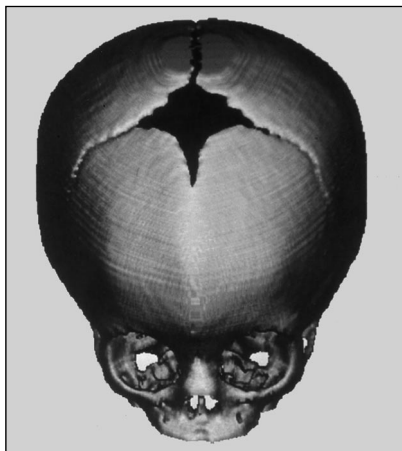


FIGURE 6. Three-dimensional reconstruction of a CT scan showing fusion of the metopic suture and trigonocephaly.

head, and 5) trapezoidal shape of the head when viewed from the vertex. (In positional deformity, the head is shaped like a parallelogram when viewed from the vertex.) If these features are absent, true synostosis is less likely.

Response to treatment can assist with the differentiation. If the head is only mildly deformed and torticollis is absent, the child should receive range of motion exercises for the neck and repositioning of the head while sleeping. If the child responds to physical therapy and changes in positioning, synostosis is extremely unlikely. If the child does not respond within 4 to 6 weeks, a plain radiograph of the head should be obtained. If this shows closed or poorly visualized sutures, a CT scan of the head with three-dimensional reconstruction should be obtained. If the radiograph shows patent sutures, but the head is not improving, the child should be referred to a plastic surgeon or neurosurgeon for further treatment.

Complications of Craniosynostosis

One of the most serious effects of craniosynostosis is increased intracranial pressure, which generally is not a problem if one suture is involved, but becomes more likely as the number of involved sutures increases. This increased pressure may be acute, leading to signs and symptoms such as headache and vomiting, or they may be more sub-

tle and eventually lead to papilledema and optic atrophy with loss of vision.

Craniosynostosis can have devastating effects on the visual system. If the bony orbits are shallow, ptosis may occur, which in addition to its cosmetic effect, may lead to exposure keratopathy. Asymmetry of the orbits may lead to ptosis or strabismus, both of which can result in amblyopia. Papilledema and optic atrophy, which initially may be asymptomatic, may occur due to increased intracranial pressure. Hypertelorism, the result of coronal synostosis, may affect conjugate vision and cosmesis.

Children who have midfacial hypoplasia that results from craniosynostosis of the sutures of the base of the skull may have problems with the upper airway, leading to stridor and apnea. For example, sleep apnea has been reported in a significant percentage of children who have Apert syndrome. Midfacial hypoplasia may lead to dental problems such as malocclusion. Occasionally, involvement of the lower airway, as with Pierre-Robin sequence, can lead to lower airway obstruction. Some conditions, such as Crouzon syndrome, are associated with abnormalities of hearing. Children who have associated cleft palate may have an increased incidence of ear infections as well. Rarely, children will have difficulty with swallowing if the mandible is involved.

Craniosynostosis severe enough to cause noticeable deformity of the skull and/or face can raise psychosocial concerns. For example, bonding and attachment in infancy may be impaired by the appearance of a child who has severe multiple craniosynostoses. School-age children who have unusual facial appearances often encounter ridicule from peers.

Treatment

NONSURGICAL TREATMENT

Children who have positional deformities without evidence of craniosynostosis often benefit from a trial of physical therapy to maximize range of motion of the neck and changes in sleeping position, such as using a sand bag against the child's

trunk and changing the position of the bed so the child has to turn his or her head the opposite way from the favored position to interact with individuals. If these are unsuccessful, molded plastic helmets can be used to reshape the head. Rarely, surgery may be needed.

SURGERY

The goals of surgical treatment in children who have true craniosynostosis are to: 1) normalize intracranial pressure; 2) allow normal growth of the brain and skull; 3) improve ocular, phonetic, nasal, and dental functioning; and 4) maximize psychological functioning. Current surgical therapy includes resection of the synostosed suture and correction of the skull and upper facial abnormalities that result from the restricted growth and compensatory changes. Older techniques, such as surgical separation at the suture site with interposition of a nonreactive plastic material, has resulted in late residual deformities and are discouraged.

Fronto-orbital osteotomies and craniotomies with cranial vault remodeling are the most common procedures for surgical correction in these patients. This surgery usually is performed by a team consisting of a plastic surgeon, neurosurgeon, and pediatric anesthesiologist. These procedures have become commonplace in many medical institutions and are associated with very low morbidity rates and with hospital stays of 4 to 5 days. Multiple fused sutures or syndromic synostosis require more complex osteotomies (Fig. 7).

During the first year of life, the brain achieves a significant portion of its adult volume and weight (Fig. 8). Therefore, surgery to free sutures and allow normal brain growth to expand the skull in normal directions needs to be performed at this early age. Multiple staged operative procedures are usually necessary with the more serious syndromic craniosynostoses such as Apert syndrome. For example, a child may have initial surgery at 6 months of age, with a second procedure at 4 years of age and a third one at age 13. A number of studies have shown that cranial volume increases

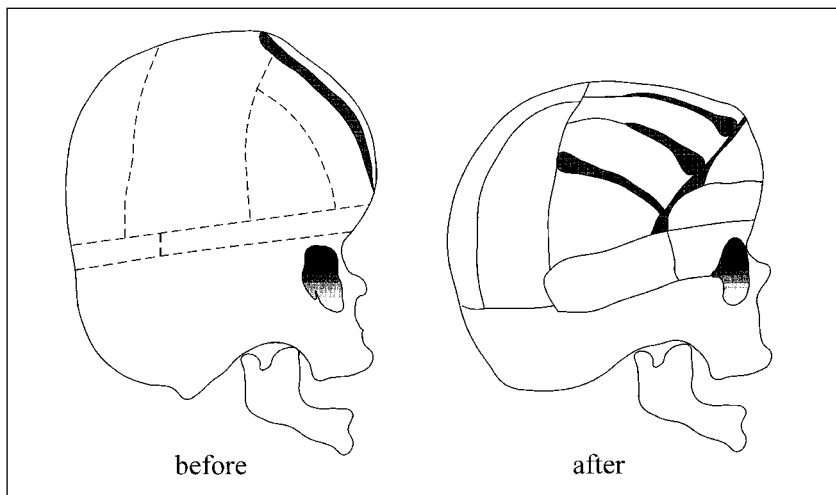


FIGURE 7. Illustration of lateral views of the skull before and after surgical remodeling in a child who has Crouzon syndrome. The dotted line indicates the areas in which bone will be cut and reshaped. The bone is reassembled as shown in the second illustration to remodel the skull. The osteotomized segments of the cranium and upper orbit are held in their corrected position with stainless steel wires or small plates and screws.

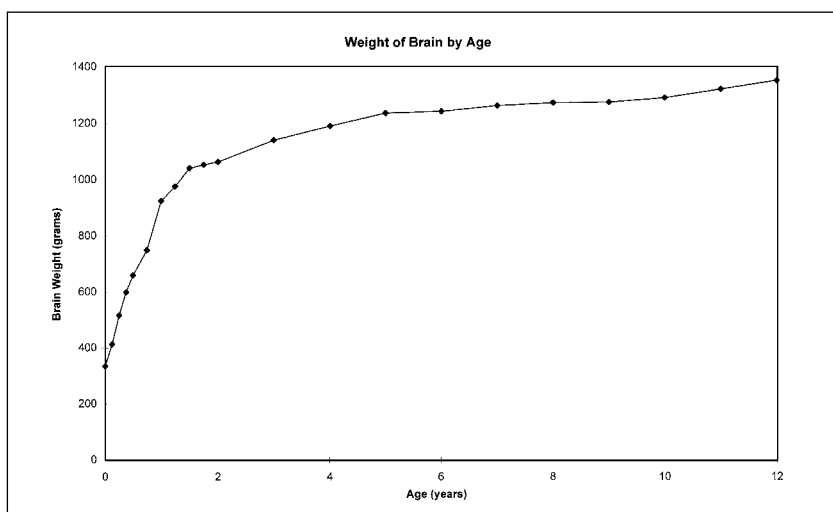


FIGURE 8. Increase in weight of brain by age. Reprinted with permission from Copoletta JM, Wolbach JB. Body length and brain weight of infants and children. *Am J Pathol.* 1933;9:55-70.

at a normal rate following this type of surgery, parallel to normal growth curves. Children also develop a significantly improved appearance of the face and skull.

Children who have complex craniosynostosis should be treated by a craniofacial team that includes plastic surgery, neurosurgery, ophthalmology, oral surgery, otorhinolaryngology, and pediatric anesthesia and critical care. The team also should include individuals familiar with the developmental, nutritional, and airway-related aspects of these conditions, such as a pediatrician,

as well as someone who can help the family with the psychological issues and provide support and access to resources, including financial counseling.

POTENTIAL COMPLICATIONS

Surgical complications are illustrated in Table 2. Although complications from most of these procedures have been exceedingly rare, the potential for eye or brain injury always is present. A leak of cerebrospinal fluid may occur, as might meningocele in which the meninges protrude through one of the openings created

TABLE 2. Complications of Surgery to Correct Craniosynostosis

- Blood loss
- Subdural hematoma
- Subgaleal hemorrhage
- Cerebrospinal fluid leak
- Meningocele
- Infection
- Intravascular air
- Pressure necrosis of skin
- Retinal damage
- Corneal drying
- Strabismus from damage to trochlea or canthal tendons
- Syndrome of inappropriate antidiuretic secretion
- Panhypopituitarism
- Risks from anesthesia

in the skull. Syndrome of inappropriate antidiuretic hormone secretion and panhypopituitarism also may occur following this surgery.

ANCILLARY EVALUATIONS

Table 3 lists activities crucial to the evaluation and treatment of a child who has severe craniofacial abnormalities, such as Apert or Crouzon syndrome. Because many of these diagnoses now are being made in the prenatal period through the use of routine ultrasonography, facilities for prenatal genetic counseling and anticipatory guidance should be provided. Genetic analysis through amniocentesis or chorionic villi sampling may be indicated. During the neonatal period, the child should be evaluated thoroughly to identify other conditions, with special attention to the areas indicated in the table.

Between 2 and 9 months of age, the child's skull and face should be evaluated by the craniofacial team. The cervical spine may need to be evaluated, as in children who have Apert syndrome, and may exhibit partial fusion. Referral to an orthodontist or oral surgeon should be made at this time. The primary surgery usually is performed during

TABLE 3. Evaluation and Treatment of Complex Craniosynostosis

| CHILD'S AGE | FACTORS TO CONSIDER | POSSIBLE CONSULTATIONS |
|---------------|---|--|
| Prenatal | Anticipatory guidance regarding the future Genetic factors | Genetics |
| Neonatal | Airway—upper airway abnormalities; consider tracheostomy Nutrition—consider gastrostomy Neurologic—rule out increased intracranial pressure; consider head ultrasonography or computed tomography, skull surgery, or ventriculoperitoneal shunt Ophthalmologic—evaluate vision and extraocular motion; consider eye lubricants Auditory—evaluate hearing Extremities—evaluate for malformations Psychosocial issues—evaluate bonding and attachment | Otorhinolaryngologist Dietitian Neurosurgeon, Plastic surgeon Ophthalmologist Audiologist Orthopedist Social worker, Psychologist |
| 2 to 6 Months | Primary Surgery Skull and face—evaluate using three-dimensional computed tomography Neck—evaluate cervical spine as indicated Airway—evaluate for stridor and apnea Ears—watch for acute otitis media; evaluate hearing Dentition—observe for abnormalities of palate and midface, occlusion Development—evaluate milestones Psychosocial issues—stress and support, financial issues, grieving | Plastic surgeon, Radiologist Orthopedist Otorhinolaryngologist Audiologist Orthodontist or Oral surgeon Early intervention specialists (eg, physical therapist, occupational therapist) Psychologist |
| 4 years | Secondary Surgery , eg, Le Fort III midface advancement | |
| Adolescence | Additional Surgeries , eg, jaw surgery, Le Fort advancement, or maxillomandibular osteotomies or genioplasty Identify transitions to adulthood | Psychologist, Transitional program |

this period. Children who have genetic or chromosomal abnormalities, as well as those who have primary brain anomalies, should undergo developmental evaluations. Throughout the entire treatment period, psychosocial issues such as stress, support, and grieving should be addressed. A national organization, FACES, the National Association for the Craniofacially Handicapped (PO Box 11082, Chattanooga, TN 374001; (800) 332-2373) provides support to parents of children who have severe involvement. For children who have simple isolated synostosis, further interventions usually are not necessary, but additional surgery may be necessary for those who have midface hypoplasia or more complex abnormalities, even through adolescence.

Conclusion

Asymmetry of the infantile head is a common occurrence. Because the optimal period for surgical correction of craniosynostosis is in the first year of life, pediatricians need to be able to differentiate positional deformations from premature closure of sutures as early in the child's life as possible. If craniosynostosis is diagnosed, its etiology should be ascertained and referral to an appropriate team made expeditiously.

Ongoing surveillance of the child who has craniosynostosis for issues related to genetic counseling, cognitive development, airway management, and nutrition, as well as psychological issues such as attachment and interaction with peers should be provided by the pediatrician. The primary care pediatrician should

assist the surgical team in the pre- and postoperative periods. The pediatrician can improve the child's care and outcomes by knowledgeable coordination of care.

SUGGESTED READING

- Becker LE, Hinton DR. Pathogenesis of craniosynostosis. *Pediatr Neurosurg.* 1995;22:104-107
- Huang MH, Gruss JS, Clarren SK, et al. The differential diagnosis of posterior plagiocephaly: true lambdoidal synostosis versus positional molding. *Plast Reconstr Surg.* 1996;98:765-776
- Opitz JM. Terminology of craniofacial anomalies. *Birth Defects.* 1990;25:27-37
- Pollack IF, Losken HW, Fasick P. Diagnosis and management of posterior plagiocephaly. *Pediatrics.* 1997;99:180-185

PIR QUIZ

11. Recently an increase in the occurrence of cranial deformations in infants older than 6 months has been reported. This increase is attributed to:
 - A. Depressed skull fracture.
 - B. Metabolic bone disease.
 - C. Microcephaly due to brain damage.
 - D. Positional deformity.
 - E. Simple craniosynostosis.
12. An isolated keel-shape deformity of the central forehead in an infant indicates:
 - A. Plagiocephaly or unilateral coronal synostosis.
 - B. Premature closure of all of the sutures.
 - C. Premature closure of the lambdoidal sutures.
 - D. Scaphocephaly or sagittal synostosis.
 - E. Trigonocephaly or metopic synostosis.
13. Which of the following diagnostic procedures is *most* useful in identifying the abnormal skull shape and which of the sutures is involved?
 - A. Cerebral arteriography.
 - B. Computed tomography of the head.
 - C. Cranial ultrasonography.
 - D. Magnetic resonance imaging of the head.
 - E. Plain radiographs of the skull.

Earning CME Credit—Completing the PIR Quiz

The American Academy of Pediatrics (AAP) is accredited by the Accreditation Council for Continuing Medical Education (ACCME) to sponsor continuing medical education for physicians. *Pediatrics in Review (PIR)* was planned and produced in accordance with the ACCME Essentials.

The AAP designates this activity for up to 38 hours in Category 1 of the Physician's Recognition Award of the American Medical Association (3 hours per completed print issue of *PIR* and 2 hours per completed compact disc issue of *PIR*). Each physician should claim only those hours of credit that he/she actually spent in the educational activity.

PIR Quiz: A short quiz can be found at the end of each article in *PIR*. Use the *PIR* Quiz Card (bound into the January issue) to record your answers. Each question has a single best answer. The answers to the questions appear on the inside front cover of each issue.

1998 Credit Deadline: *February 28, 1999.* If you want to receive CME credit in 1998, the *PIR* Quiz Card must be received in the PREP Office by February 28, 1999. Credit reply material received after February 28, 1999, will be applied to the following year.

Expiration of Credit: *December 31, 2000.* Credit for completing the 1998 PIR will be awarded for up to 2 years. Credits will be posted to the year in which they are submitted.

Verification of Credit will be mailed by: *April 30, 1999.* You will receive a complimentary transcript by April 30, 1999, containing a summary of CME credits earned in 1998 through AAP programs. If you require a transcript at any other time of the year, there will be a \$25 processing fee.

Mail form to: *American Academy of Pediatrics - PREP Office, 141 Northwest Point Boulevard, PO Box 927, Elk Grove Village, IL 60009-0927*

PREP Education Award: The AAP PREP Education Award recognizes Academy Fellows and Candidate Fellows who earn a minimum of 150 AAP-approved CME credits over 3 consecutive years. The Award will be mailed July 1999 to all individuals who qualify. To qualify for the PREP Education Award, an Academy Fellow or Candidate Fellow must:

- Earn a minimum of 75 credit hours through participation in PREP or PREP: The Course, and
- Earn the remaining credit hours (75 hours) through other Academy-sponsored or -approved CME

activities, including AAP Spring Session of Annual Meeting, AAP CME courses, ACQIP, Pediatric UPDATE Audiocassette Tape Program, or other AAP-approved courses.

Other Organizations Granting Credit: *PIR* has been approved for credit as follows:

- *American Academy of Pediatrics (AAP);* up to 38 hours of credit toward the AAP PREP Education Award
- *American Osteopathic Association (AOA);* up to 12 hours, Category 2-B
- *National Association of Pediatric Nurse Associates and Practitioners (NAPNAP);* up to 38 contact hours
- *Canadian Paediatric Society* has approved PREP as one method for pediatricians to demonstrate maintenance of competence (MOCOMP)
- PREP has been reviewed and accepted by the *American Academy of Family Physicians (AAFP)* for up to 38 Prescribed hours. Term of approval begins January 1998. Enduring materials are approved for 1 year with the option to request renewal.

Consultation with the Specialist: Pediatric Approach to Craniosynostosis

Gregory S. Liptak and Joseph M. Serletti

Pediatrics in Review 1998;19;352

DOI: 10.1542/pir.19-10-352

| | |
|---|---|
| Updated Information & Services | including high resolution figures, can be found at: http://pedsinreview.aappublications.org/content/19/10/352 |
| References | This article cites 4 articles, 1 of which you can access for free at: http://pedsinreview.aappublications.org/content/19/10/352#BIBL |
| Subspecialty Collections | This article, along with others on similar topics, appears in the following collection(s): Genetics http://pedsinreview.aappublications.org/cgi/collection/genetics_sub Dysmorphology http://pedsinreview.aappublications.org/cgi/collection/dysmorphology_sub |
| Permissions & Licensing | Information about reproducing this article in parts (figures, tables) or in its entirety can be found online at: /site/misc/Permissions.xhtml |
| Reprints | Information about ordering reprints can be found online: /site/misc/reprints.xhtml |

American Academy of Pediatrics

DEDICATED TO THE HEALTH OF ALL CHILDREN™



Erratum

As many readers have informed us via letter or telephone, there is an error in the answer key of the October 1998 issue (referring to the article on craniosynostosis). The answers to questions 11 and 12 (page 359) are: #11: D, not E; #12: E, not A.