

PediatricsⁱⁿReview[®]

Common Gynecologic Problems in Prepubertal Girls

Naomi F. Sugar and Elinor A. Graham

Pediatrics in Review 2006;27;213

DOI: 10.1542/pir.27-6-213

The online version of this article, along with updated information and services, is located on the World Wide Web at:

<http://pedsinreview.aappublications.org/content/27/6/213>

Data Supplement at:

<http://pedsinreview.aappublications.org/content/suppl/2006/05/02/27.6.213.DC1.html>

Pediatrics in Review is the official journal of the American Academy of Pediatrics. A monthly publication, it has been published continuously since 1979. Pediatrics in Review is owned, published, and trademarked by the American Academy of Pediatrics, 141 Northwest Point Boulevard, Elk Grove Village, Illinois, 60007. Copyright © 2006 by the American Academy of Pediatrics. All rights reserved. Print ISSN: 0191-9601.

American Academy of Pediatrics

DEDICATED TO THE HEALTH OF ALL CHILDREN™



Common Gynecologic Problems in Prepubertal Girls

Naomi F. Sugar, MD,*
Elinor A. Graham, MD,
MPH[†]

Author Disclosure
Drs Sugar and
Graham did not
disclose any financial
relationships relevant
to this article.

To view a *Suggested Reading list* for this article, visit www.pedsinreview.org and click on this article title.

Objectives After completing this article, readers should be able to:

1. Describe techniques to perform an adequate and gentle genital examination in a school-age girl.
2. Discuss the differential diagnosis for vaginal bleeding in the prepubertal girl.
3. Identify a strategy to diagnose and treat vaginitis in the prepubertal child.

Introduction

Assessing gynecologic symptoms and signs in prepubertal children can be a challenge for pediatricians. Adult pelvic examinations are a standard part of medical school education, and learning objectives for the American Board of Pediatrics emphasize knowledge of adolescent gynecology. Pediatric practice standards recommend routine external examinations for girls of all ages at health supervision examinations. Unfortunately, pediatricians often lack training in examination techniques, determination of normal findings, and gynecologic pathology of infants and prepubertal children.

In the past decade, a high level of concern for child sexual abuse and emphasis on the sentinel role of pediatricians in recognizing abnormalities due to child abuse paradoxically has left pediatricians and other child health clinicians more anxious and uncomfortable in performing these examinations. However, although child sexual abuse is common, it rarely is diagnosed primarily by physical complaints. It is much more likely that a girl who is brought to the physician because of genital symptoms has either normal variant findings or a nontraumatic disorder. (1) The aim of this article is to review normal anatomy and physiology in infants and prepubertal children, emphasizing developmental changes, normal variants, and the differential diagnosis for common signs and symptoms.

Developmental Anatomy and Physiology

Infant and Toddler

The newborn girl is affected by maternal estrogens that cross the placenta. Breast buds are usual, and a milky discharge from the nipples is not uncommon. Like her mother, the neonate may develop mastitis. Vaginal discharge is common in newborns, as are long hymenal tags that frequently are visible, extending outside the vestibule. The vaginal epithelium also demonstrates the estrogen effect. The epithelium contains glycogen, and vaginal secretions are acidic. The newborn's vagina is approximately 4 cm long. The cervix is much larger than the uterine corpus (ratio 3:1).

Even after maternal circulating estrogen concentrations decline, the infant girl maintains relatively high endogenous production of gonadal estrogens. Hymenal tissue, sensitive to estrogen, remains thick, redundant, and elastic throughout infancy. Most commonly, the hymen surrounds the vaginal orifice and appears circumferential (Fig. 1A). In some infants, the hymen extends outward in a sleeve-like configuration. The clitoral hood is prominent, and the urethra may be obscured by redundant hymenal tissue.

The Preschool and School-age Child (Ages 3 to 6 y)

As the hypothalamic-pituitary-gonadal axis becomes suppressed, the hormonal effects on the genital structures recede (Fig. 1B). The labia become flatter and the clitoris less prominent. The labia minora throughout infancy and childhood are rudimentary, appear-

*Clinical Associate Professor, Department of Pediatrics, Division of General Pediatrics, University of Washington, Seattle, Wash.

[†]Associate Professor, Department of Pediatrics, Division of General Pediatrics, University of Washington, Seattle, Wash.

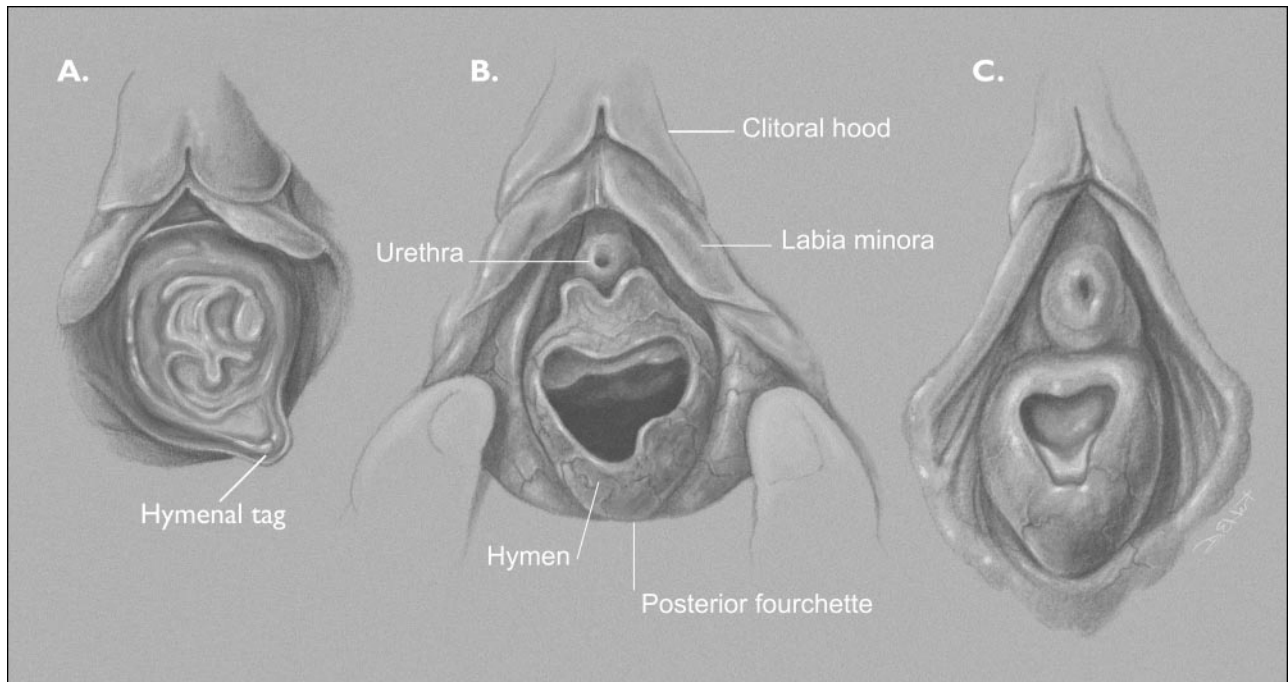


Figure 1. Developmental changes in genital morphology. A. Infant: Hymen circumferential and redundant. B. Preschool through school age: Rudimentary labia minora, thinner hymen. C. Early puberty: Labia minora develop, hymen thickens.

ing as an extension of the clitoral hood, and extend only about one third the length of the labia majora. In this age group, the hymen becomes thinner and may be translucent, although some children maintain a thickened, redundant hymenal configuration. The hymen tissue often recedes from the anterior vaginal orifice, leaving a “crescentic” appearance. (2) The degree of variability, however, is high, and some children show these changes as early as 2 years of age, while others may retain the typical infantile thickened hymen as late as 7 or 8 years of age. Single or multiple hymenal tags may be seen, but often are visible only if the examiner uses a few drops of water or saline to “float” the hymenal tissue during the examination. (3) The vaginal epithelium becomes thin, and the vaginal pH is alkaline. A vaginal swab shows ovoid epithelial cells.

Older School-age and Preteen Children (Ages 7 to 12 y)

Sexual Maturity Rating (SMR) staging (also known as Tanner staging) is based on breast development and pubic hair. Changes in the genital tissues are usually visible before breast buds (which are palpable as firm glandular tissue under the nipple) form and before pubic hair growth begins (SMR 2). The mons becomes fuller, as do the labia majora. The labia minora continue to

develop, although it is only years after menarche that the labia minora become a completely separate layer and join at the posterior commissure. The vestibular mucosa develops a cobblestoned, rough appearance. The hymen thickens and often develops fimbriations (Fig. 1C). The vagina elongates to about 8 cm, the uterine corpus enlarges, and the vaginal mucosal thickens. A milky vaginal discharge may be noted, vaginal secretions become acidic, and lactobacilli become the predominant organism. A vaginal swab shows polygonal epithelial cells. Physiologic leukorrhea commonly precedes menses by 3 to 6 months.

Examination Techniques

The basic requirements for the genital examination are adequate lighting and a relaxed patient. When the child is tense, she will have difficulty maintaining a frog-leg position and will contract the gluteal and perineal muscles, making an adequate examination impossible. Magnification usually is not necessary, but an otoscope or magnifying visor may be used. An adequate external genital-anal examination takes only 5 to 30 seconds to complete.

The usual pediatric methods of helping a child through an examination should be used, including explaining to the child what the examiner is doing and

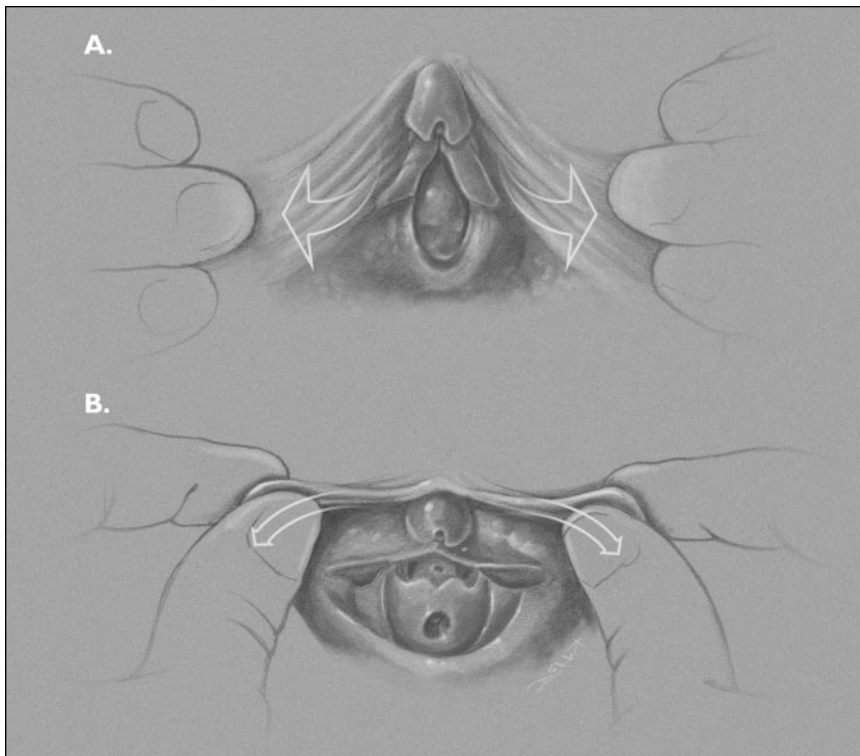


Figure 2. Examination techniques. A. Labial separation. B. Labial traction. Examiner gently grasps the labia minora and pulls forward and out to visualize the entire introitus.

engaging the child in distracting conversation. For any age child, a genital examination that requires either physical or psychological force cannot result in accurate examination findings and may lead to fear on the part of the patient and her parent.

Infant and Toddler

The newborn girl is examined in the nursery. The genital examination naturally follows the hip examination when the baby's hips are flexed and adducted. Placing the hands on each thigh, the examiner can use his or her thumbs to separate the labia majora (Fig. 2A). A second technique, labial traction, allows better visualization of the introitus and consists of gently grasping the labia with thumb and forefinger and gently pulling the labia toward the examiner (Fig. 2B). If the redundant hymen obscures the orifice, the examiner may drop a little warm water or saline into the introitus to assure that the hymen is perforate. Most pediatricians examine infants through the first postnatal year similarly on the examination table. Once again, the genital examination follows the evaluation of the hips and the diaper area skin and is followed by a brief anal examination.

For toddlers, examinations of the diaper area are as

pleasant as ear examinations. Most toddlers object to being touched, and the pediatric examiner must choose his or her battles wisely. One method is to incorporate the brief genital-anal examination into a diaper change on the table. If there is a concern or problem, however, the evaluation must be more detailed. Often, it is easiest to examine the genital area while the child is sitting in a modified frog-leg position on a diaper in her parent's lap.

Preschool-age Children

For preschoolers, the examination may be perceived as intrusive and against the rules, especially if the parent has told the child, "Don't let anyone look down there!" For some cultural or ethnic groups, the genital examination appears inappropriate. It may be difficult for any parent who has not developed a trusting relationship with the clinician to convey to the child that

examination of the private parts is normal and safe.

If the parent is uneasy, the child will be uncomfortable and anxious. It is most important to discuss the examination with the parent before initiating it. The physician should assure the parent that this is a usual part of the physical examination and obtain the parent's assent.

Each clinician develops his or her own methods for moving smoothly through the examination. Some clinicians may move the child's legs into the frog-leg position when the child is placed supine for the cardiac and abdominal evaluations to allow the genital examination without a position change. Others may have the child remain sitting while explaining that her legs will move into a position like "butterfly wings" with the soles of her feet together and then asking her to lie back. Another option is to have the parent sit on the examination table with the child on her lap.

Labial separation and labial traction allow good visualization of the entire introitus. The prone knee-chest position is useful when the examiner needs to see the vaginal vault because of concern for a foreign body. The child lies with her chest on the examination table, supporting her weight on her knees, with her buttocks elevated.

School-age and Preteen Children

Children may be embarrassed at this age, and several methods may help them maintain their modesty. Drapes always should be used. Rather than removing the underpants completely, an alternative is to place the child in the frog-leg position and move the crotch area of the underpants to the side. This maneuver often allows an adequate view, and many children are more comfortable with this method. It is reasonable to ask the parent to stay by the child's head on the examination table and to ask the father, other male relatives, or male interpreter, if present, to leave the room briefly during this part of the examination. If the parent or guardian is not in the examination room, a staff chaperone should be present. The clinician can enlist the child's intellect and interest in the examination by explaining, with illustrations, what the genital area normally looks like and why it is helpful to know if each of the three openings in that area of the body appears normal. This active engagement assists the child in mastering the medical examination process.

Normal Anatomic Variants

Pigmentation variations may be noted and should not be confused with bruises. More darkly pigmented children may show darker areas on the superior labia minora and clitoral hood.

Periurethral bands are visible in most patients when labial traction is employed (Fig. 2B). Such bands of tissue extend from the urethra, creating a false pocket on either side. The pockets can be confused with the actual urethra, which usually appears as a small midline dimple. Sometimes the urethra is dilated, which may present another unexpected configuration. Urethral dilatation is a simple variant and is not a sign of trauma or disease. Perihymenal bands may extend from the hymen to the vestibular wall.

Deep notches or absent areas of hymen are noted routinely in the superior half of the hymen. Although it is possible that such clefts are the result of trauma, they have been noted in multiple studies of nonabused girls (3) and are normal as the hymen changes from circumferential to a crescentic configuration. Hymenal tags may lie inside the vaginal canal and give the appearance of a deep notch or absent hymen posteriorly. Intravaginal ridges and rugae are normal. An external hymenal ridge sometimes is seen (Fig. 3), and a midline avascular area on the fossa navicularis (linea alba) is common.

The size of the hymenal orifice varies widely. The orifice diameter is affected by examination technique, position, and contraction or relaxation of the perineal muscles. In one recent study of nonabused 4- to 8-year-

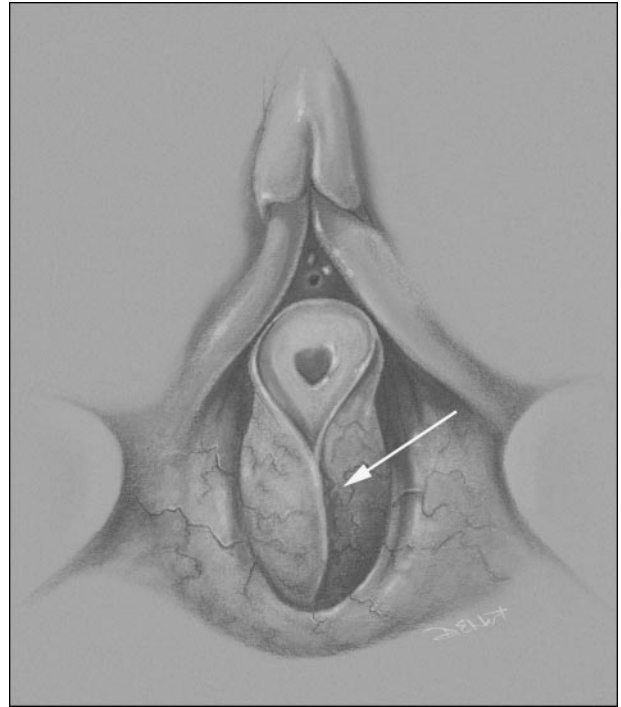


Figure 3. External hymenal ridge (arrow) and sleeve-like hymen, a normal variant.

olds, the horizontal diameter ranged from 1 to 10.5 mm. (4) Thus, the diameter is of little use in distinguishing abused from nonabused girls.

Rarely, fusion of the perineum during embryogenesis is incomplete, resulting in a defect termed “failure of midline fusion.” This finding appears as a wedge of visible submucosa near the anus or anteriorly near the posterior fourchette. Although initially it may be perceived to be an open wound, careful inspection reveals symmetry and no signs of healing. In questionable cases, a re-examination in 1 week should resolve the question. Perineal failure of midline fusion has no known complications.

Imperforate hymen is another failure of normal embryologic development. In the newborn period, a bulging mass (hydrocolpos) may be noted at the introitus (Fig. 4). If not recognized and corrected surgically in infancy, the condition typically is quiescent until puberty, when the patient presents with abdominal pain and the absence of menarche, and the presence of hydrometrocolpos is recognized. A small, high hymenal orifice should not be misinterpreted as imperforate; the natural history of this hymenal configuration is not known.

Diaper rash is common in toddlers, and this constant irritation may lead to labial adhesions. Typical labial

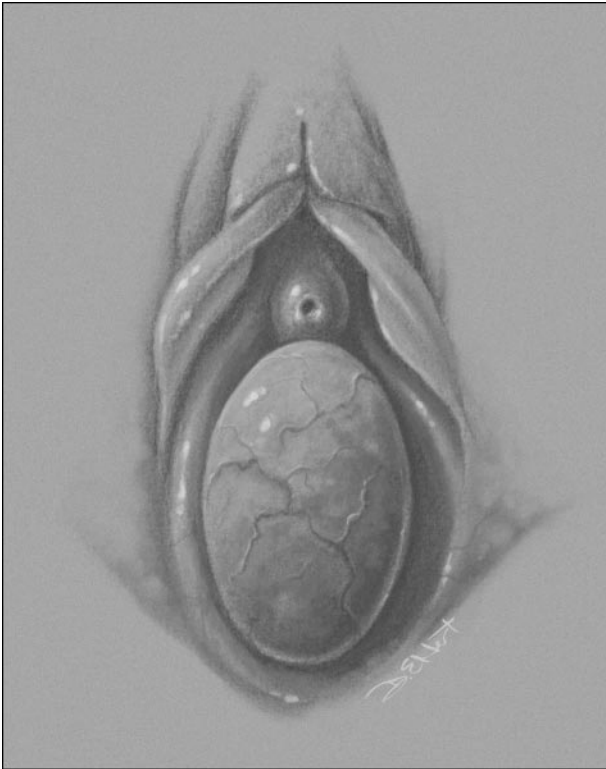

Figure 4. Imperforate hymen. Hydro- or hydrometrocolpos is recognized by bulging tissue.

adhesions start at the posterior introitus and may be as small as a few millimeters or so extensive that the entire introitus is obscured. Although previous recommendations were to lyse such adhesions, this treatment is both painful and of little use because the adhesions usually re-form. In those rare cases when there is only a pinpoint orifice and urine outflow is impeded, many clinicians choose to treat with estrogen cream. By causing maturation and thickening of the epithelium, the adhesion resolves. One regimen is to have the parent apply a small amount of conjugated estrogen cream directly to the adhesion once a day for 10 days, then every other day for the next 10 days. Unfortunately, topical estrogen is absorbed easily, parents often apply more cream than recommended, and toddlers frequently develop breast budding as well as hymenal thickening and vaginal discharge during treatment. For this reason, the instructions must be explicit and include a demonstration of the application technique, and the treatment must be monitored closely and terminated as soon as the adhesion is resolved. In susceptible children, adhesions recur as long as the child is in diapers and sometimes even longer. For the girl who is potty-trained, good hygiene may necessari-

tate daily baths. The clinician must determine when adhesions are causing functional disability or symptoms and when they should be tolerated as a variant that will resolve with maturation.

Vaginal Bleeding

Case 1

A 2-month-old girl presents with blood in her diaper. She attended child care as usual yesterday and seemed normal in the evening. Her diaper was changed quickly at night, and blood was noted in her diaper this morning. The parents are distressed that their child may have been sexually abused in the child care center. The child is afebrile, playful, and active. The diaper in question shows a small amount of dark red streaking. Results of the general examination, including the abdomen, are benign. Examination of the genital area shows normal labia, perineum, and anus. A bulging dark red-to-black mass obscures the introitus (Fig. 5).

Although the primary concern of parents is sexual abuse, this rarely presents as painless vaginal bleeding. Very small amounts of vaginal bleeding are common in the first weeks after birth. This blood is uterine in origin and represents withdrawal bleeding as maternal estrogen levels decline in the infant.

When an older infant or child presents with a complaint of vaginal bleeding, the clinician must ask the following questions: Is it really blood? Where is it from? Reddish or brown staining on the diaper or underpants may be stool, blood in the stool, blood in the urine, or red-stained urine. The next step is a general physical examination, with emphasis on height, weight, and secondary sexual characteristics. Menarche normally occurs at SMR 3 or 4 breast development. If the girl has SMR 1 breasts (no breast tissue) or SMR 2 breasts (only breast budding), she cannot be having a normal first menstrual period.

Urethral Prolapse

Urethral prolapse was the cause of painless vaginal bleeding in Case 1. Urethral prolapse may present as early as the toddler years or as late as adolescence. Prolapse is more common in African-American than Caucasian girls. On examination, a vascular “donut,” a ring of congested, edematous tissue, is noted at the introitus. The vaginal orifice may be obscured entirely. The prolapsed mucosa appears red or purple, and areas may appear black or even necrotic. Urethral prolapse is caused by a weakness in the supporting tissues of the urethra. Although no therapeutic trials have been conducted, clinicians have reported a good response to application of estrogen cream. A small

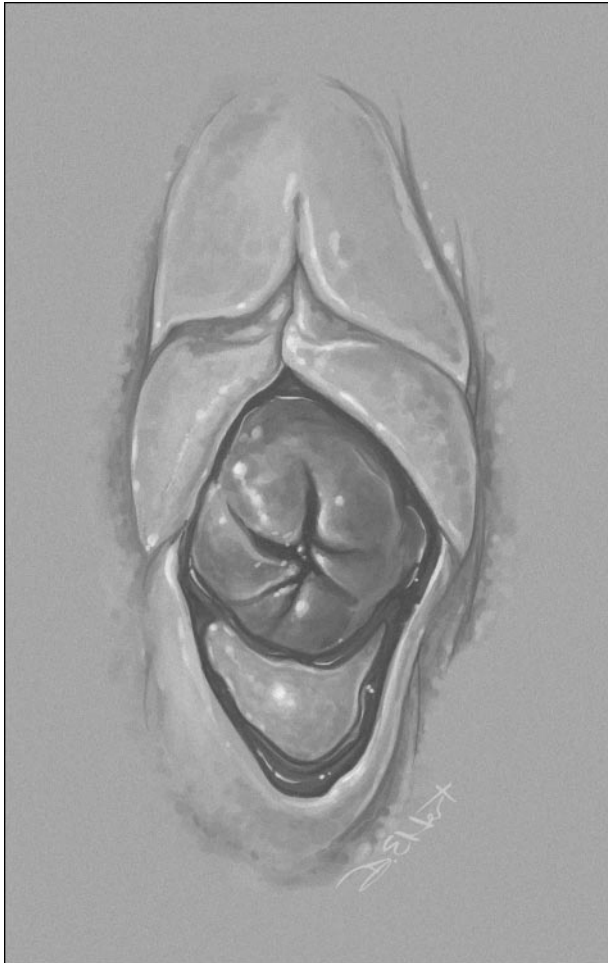

Figure 5. Urethral prolapse: a donut of red, purple, or dark tissue surrounds the urethra and obscures the hymenal orifice.

amount of the cream is applied to the affected areas daily for 1 week, then every other day for the next week. Warm sitz baths may be effective. Straining with defecation may exacerbate the prolapse, and stool softeners may be helpful. If conservative treatment is ineffective or if the child is unable to urinate at presentation, surgical intervention may be warranted.

Lichen Sclerosus et Atrophicus

Another cause of painless bleeding is lichen sclerosus et atrophicus, which probably is an autoimmune condition and is more common in postmenopausal women. The child may complain of genital itching. Inspection reveals pale, atrophic skin in a figure eight pattern around the anus and vulva. The atrophy does not extend into the introitus. The atrophic skin is marked by subepithelial hemorrhages, which are caused by the mild trauma of

Table. Differential Diagnosis of Vaginal Bleeding

Visible Lesion

- Lichen sclerosus et atrophicus
- Urethral prolapse
- Straddle injury
- Penetrating injury (accident or abuse)
- Genital warts
- External hemangioma
- Precocious puberty*
- Pseudoprecocious puberty*
- Neoplasm—vulva or lower vagina

No Visible Lesion

- Neonatal withdrawal bleeding
- Hematuria
- Rectal bleeding
- Infectious vaginitis (*Shigella*, *Salmonella*)
- Vaginal foreign body
- Blood dyscrasia
- Exogenous hormone withdrawal
- Isolated premature menarche
- Neoplasm—upper vagina or uterus

*Secondary sexual characteristics present

scratching, wiping, or rubbing of clothing. At times, lichen sclerosus et atrophicus may present in an incomplete variant or forme fruste, with the figure eight pallor only.

Lichen sclerosus may be treated conservatively with 1% hydrocortisone cream or ointment as needed, with the expectation of episodic exacerbation, at least until puberty. Treatment with high-potency topical steroid cream can lead to prolonged remission in older women. (5) However, pediatricians may be reluctant to risk the adverse effects of this treatment. Pilot studies suggest that topical tacrolimus and pimecrolimus can be effective treatments, but recent concerns of possible carcinogenic potential of these medications may limit their use. (6)

Other causes of vaginal bleeding are obvious on inspection and include severe diaper rash, genital warts, an ulcerating hemangioma, or a penetrating injury (Table). Straddle injuries may be unobserved by the parent and unreported by the child; they typically present with unilateral labia majora laceration or bruising. Further evaluation, including examination under anesthesia, is required if results of the external examination are normal and the bleeding persists. Embryonal carcinoma and rhabdomyosarcoma of the vagina have been reported.

Vaginal Discharge

Case 2

A 6-year-old girl presents with wetness and yellow staining of her underpants on and off for the past 3 weeks. Her mother reports that the girl is touching her crotch frequently and seems to be masturbating, although she may just be scratching herself. There is no previous history of a discharge like this and no known new exposures. She appears well. The genital examination shows redness of the medial surfaces of the labia majora and a yellow vaginal discharge, which has accumulated at the posterior fourchette and around the urethra.

Vulvovaginitis

Vaginal discharge is a common symptom in young girls and signifies a vulvar or vaginal inflammation that may be caused by physical, chemical, or infectious irritants. In two recent series, bacterial causes were found in only one third of young girls who presented with vulvovaginitis. (7)(8) Most children were assessed to have either non-specific or irritant vulvitis. One author argues that non-specific vulvovaginitis should be considered a variant of atopic dermatitis, and some children are prone to vulvitis because they are highly sensitive to a variety of irritants, including soaps, poor hygiene, and tight-fitting clothing. (9) Improved hygiene with daily or twice-daily sitz baths as well as avoidance of bubble bath, soap, and shampoo in the bathtub are suggested as management techniques.

Bacterial pathogens also can cause vulvovaginitis. Respiratory pathogens are the bacteria isolated most often. Group A beta-hemolytic *Streptococcus* is the pathogen identified most commonly in all cases of vulvovaginitis and may cause, in addition to a nonspecific discharge, a dramatic scarlet, well-demarcated dermatitis of the vulva or perianal tissues. (7) *Haemophilus influenzae* (nonencapsulated) is another common pathogen. These bacterial infections are likely to be caused by self-inoculation as a child carries bacteria from her nose and mouth via her hand to her vulva. Enteric pathogens, *Escherichia coli*, *Salmonella* sp, and *Shigella* sp also may cause vaginitis; the latter two organisms are known to cause bloody vaginitis. Rarely, vaginitis may be the earlier or more prominent sign, with only mild diarrhea. The presence of leukocytes on the smear of the discharge is sensitive but not specific for bacterial infection.

Foreign Body

A vaginal foreign body may cause a persistent, foul-smelling, bloody or brown discharge. The most common foreign body is small bits of toilet paper, although larger objects such as coins, bottle caps, or small toys may be

inserted by the child. If the foreign body is visible and the patient is cooperative, a plastic ear curette can be used to hook the foreign body and pull it out. Irrigation also may be used to flush out the foreign body. A soft feeding tube or red rubber catheter is inserted into the vagina to irrigate with warm water. An association has been noted between a history of sexual abuse and retained foreign bodies. When treating a child who has a foreign body, questioning both the parent and the child about possible abuse is warranted.

Pinworms

Pinworms may cause another type of irritant vulvitis. Although pinworms do not reside in the vulva, they can crawl from the anus to the vulvar introitus and cause intense pruritus. The interview should identify pruritus as the prominent symptom. The diagnostic test is an anal pinworm preparation. Empiric treatment is recommended if pinworms are suspected.

Candidal Infection

Candida frequently causes diaper dermatitis and vaginitis in adolescents and adults. Infection may occur in a school-age child who has been receiving oral antibiotic therapy, but it is very uncommon in children who are out of diapers and otherwise well.

Sexually Transmitted Infections

Sexually transmitted infections may present with vaginal discharge. Gonorrhea in children is a vaginal infection and rarely is associated with ascending infection. The vaginal discharge typically is profuse and green. Gonorrhea is diagnosed more often in children who present with a complaint of vaginal discharge than in those who present for evaluation of sexual abuse. (10) *Chlamydia* infection may be asymptomatic or present with a clear vaginal discharge. Both *Chlamydia* and gonorrhea may be transmitted perinatally from an infected mother. Gonorrhea typically presents with signs, but asymptomatic carriage of perinatally acquired *Chlamydia* has been documented to 34 months of age. (11)

Other

Other uncommon causes of vaginal discharge include fistula, ectopic ureter, polyps, neoplasms, *Trichomonas* infection, and infection caused by other respiratory, enteric, or opportunistic organisms.

Evaluation

A practical process for evaluating the report or finding of vaginal discharge follows. If the discharge is clear, scant, and accompanied by itching, a regimen of sitz baths and avoidance of irritants is a reasonable first step. If itching is intense and worse at night, treatment for pinworms may be prescribed. If the vaginitis persists, a follow-up in 2 weeks should be arranged; a culture of the inner labia can be obtained at that time. The clinician can obtain a culture by moistening a regular culture swab with non-bacteriostatic water or saline and gently touching the inner labia and posterior fossa. It is not necessary to insert either a swab or catheter into the vaginal canal. The specimen should be sent to the laboratory with a request for microbiologic assessment for respiratory pathogens, group A beta-hemolytic *Streptococcus*, enteric pathogens, and gonococcus. If, on the other hand, the child presents with a profuse green discharge or has blood-streaked or foul-smelling discharge, culture for respiratory and enteric pathogens and gonococcus should be obtained without waiting 2 weeks. A positive culture for gonorrhea should prompt an evaluation for sexual abuse.

When cultures are negative and significant vaginitis persists, the clinician should consider infection with *Chlamydia* as well as a vaginal foreign body. A urine screen for *Chlamydia* by DNA or RNA amplification test is recommended by some experts. Because nonculture amplification tests have not been evaluated fully in children, a positive amplification test mandates a confirmatory test using a different method or culture. (12) High suspicion for a foreign body without visualization warrants referral to a gynecologist for consideration of examination under anesthesia. Finding a sexually transmitted infection in a child mandates consultation with an expert in child sexual abuse as well as referral to child protective services. (13)

Female Circumcision

Case 3

The parents of a 3-year-old child recently adopted from Africa bring her in for a physical examination and ask if you see any evidence that she has had a female circumcision because this procedure is known to be done in the region where she was born. Her external genitalia appear normal except that tissue over the clitoris appears smaller than usual. A bump of clitoral tissue is palpable. You never have seen a girl who has undergone female circumcision and are unsure of how to advise the parents.

Types of Procedures and Presentation

Female circumcision, or ritual female genital surgery (RFGS), has received substantial attention in the popular press for the past several years. The age at which the procedure is performed varies from newborn in Ethiopia to the prepubertal period in Somalia and Sudan and during pregnancy in Nigeria. Countries in which more than 80% of the adult female population have had RFGS include Ethiopia, Eritrea, Somalia, Sudan, and Sierra Leone. Over the past century, however, RFGS has been practiced in more than 30 countries worldwide and by many religious groups. Public health campaigns and efforts to make the procedure illegal have curtailed the number of procedures in many countries.

Although a minority of procedures produces drastic changes in the appearance of the external genitalia, procedures vary greatly by region and by the traditional healer who performs them. (14) Immigrant girls in the same family often undergo completely different procedures, depending on where they live and who does the procedure. Results vary from no change to complete removal of the labia minora, clitoris, and labia majora, leaving a midline surgical scar and a small single opening in the introitus (Fig. 6). The extreme procedure is termed “infibulation” and can interfere with sexual functioning as well as require special attention to performance of an anterior episiotomy at delivery. Many procedures do not involve removal of significant amounts of tissue, and the girl may show no evidence of a scar or only a small scar or attenuation of clitoral tissue, as noted in this child. Clinicians have documented that among adult African female immigrants who provide a history of RFGS, results of the genital examination may appear normal. In normal children, clitoral hood tissue and clitoral size vary substantially, and the clitoral body may be palpated better than seen. Minor changes are difficult to evaluate when no history is available.

The most severe complications of RFGS relate to the immediate risks of infection and hemorrhage. Ritual surgeries (including male circumcision, uvulectomy, and dental procedures) often are performed under less-than-sterile conditions and carry a risk of viral and bacterial infection transmitted by instruments used in the surgery. Serology for human immunodeficiency virus, hepatitis B, and hepatitis C are indicated in this child and other children who have evidence of past ritual surgery in countries where the prevalence of such diseases is high.

The physical findings in girls who have had procedures involving extensive removal of tissue and major changes in the size of the introitus are sufficiently dramatic not to be missed on careful examination. If the

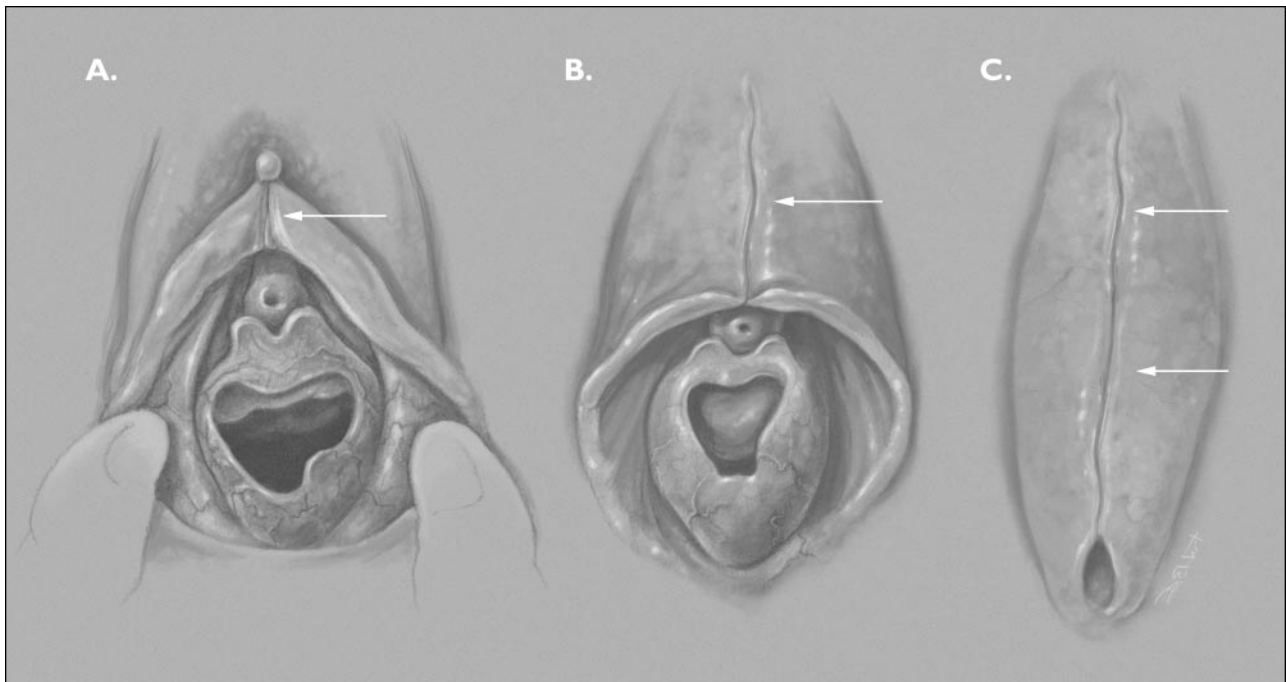


Figure 6. Ritual female genital surgery. A. Minimal surgery: history of incision with no tissue removal. B. Moderate procedure: labia minora and clitoral hood excised and sutured. C. Infibulation: Major excision and sutural closure of vaginal orifice.

vaginal opening is not decreased in size, intercourse in adulthood is unlikely to be painful. Clitoral tissue is only part of the tissue around the vaginal introitus that becomes engorged with sexual stimulation; adult women who have had extensive procedures describe orgasmic sensations with intercourse. The parents of this child can be reassured that if she did have a procedure, it is unlikely to interfere with development and sexual function.

Precocious Puberty

Case 4

You are seeing a 6-year-old African-American child for a health supervision visit. She has SMR 2 pubic hair that has developed over the past year, but no breast buds are palpable. Her height and weight are both at the 90th percentile, and a review of her systems and physical findings otherwise is normal. Her mother started her menses at age 12 years. You are unsure if you need to evaluate the child for premature puberty.

The first step in determining the presence of precocious puberty is to examine the hymen carefully for evidence of estrogen. Early pubertal changes include loss of the abundant fine vasculature of the prepubertal hymen, thickening of tissue, and slight white vaginal secre-

tions as well as elongation of the labia minora. If these changes are *not* present, the finding for the girl in the case likely represents isolated early onset of pubic hair, which is common among African-American girls. At age 6 years, SMR 2 pubic hair was found in 9.5% of African-American girls compared with 1.4% of Caucasian-American girls in a large study of 17,077 healthy girls. New guidelines from the Pediatric Endocrine Society recommend evaluation only if either breast or pubic hair development occurs before age 7 years in Caucasian-American girls and before age 6 years in African-American girls. (15)

If breast buds are palpable and maturational changes are visible on the genital examination, the girl in the case may have true precocious puberty. An unusual cause of precocious puberty is exogenous hormones from hair care products. Use of products in which estrogen and “placental products” are added to hair oils and conditioners is common among African-American families (45% to 64% in two surveys). One case series of premature pubarche and thelarche reported four cases in which hormone-containing hair care products were used on the children; after discontinuation of the products, the breast or pubic hair development receded.

Sexual Abuse

Parents and teachers often fear that any vulvar or vaginal abnormality or symptom is a result of sexual abuse. A diagnosis of variant anatomy, labial fusion, or vulvovaginitis may reassure the parent, but the presenting physical complaint may be the stated reason for a more deep-seated concern. No examination is complete without a discussion with the parents about their questions regarding this issue.

Summary

Patient cooperation and relaxation are essential to performing a thorough genital examination, and instrumentation rarely is needed in pediatric gynecologic examinations. It is important to remember that the timing of female prepubertal genital development varies widely, and anatomic variants such as failure of midline fusion must be distinguished from trauma. Vulvovaginitis in prepubertal girls often is nonspecific, and respiratory pathogens comprise most specific bacterial causes of vaginitis. Sexual abuse is one of many causes of vaginal bleeding. Ritual female genital surgery is practiced in many areas of the world, and practice varies from minimal to major excisional surgery, with varying functional effects. Guidelines from the Pediatric Endocrine Society define lower age limits for pubertal development in African-American than in Caucasian-American girls.

References

1. Kellogg ND, Parra JM, Menard S. Children with anogenital symptoms and signs referred for sexual abuse evaluations. *Arch Pediatr Adolesc Med.* 1998;52:634–641
2. Berenson AB, Grady JJ. A longitudinal study of hymenal development from 3 to 9 years of age. *J Pediatr.* 2002;140:600–607
3. Myhre AK, Berntzen K, Bratlid D. Genital anatomy in non-abused preschool girls. *Acta Paediatr.* 2003;92:1453–1462
4. Berenson AB, Chacko MR, Wiemann CM, Mishaw CO, Friedrich WN, Grady JJ. Use of hymenal measurements in the diagnosis of previous penetration. *Pediatrics.* 2002;109:228–235
5. Neill SM, Ridley CM. Management of anogenital lichen sclerosus. *Clin Exp Dermatol.* 2001;26:637–643
6. Goldstein AT, Marinoff SC, Christopher K. Pimecrolimus for the treatment of vulvar lichen sclerosus in a premenarchal girl. *J Pediatr Adolesc Gynecol.* 2004;17:35–37
7. Stricker T, Navratil F, Sennhauser FH. Vulvovaginitis in prepubertal girls. *Arch Dis Child.* 2003;88:324–326
8. Jaquier A, Stylianopoulos A, Hogg G, Grover S. Vulvovaginitis: clinical features, aetiology, and microbiology of the genital tract. *Arch Dis Child.* 1999;81:64–67
9. Paek SC. Pruritus vulvae in prepubertal children. *J Am Acad Dermatol.* 2001;44:795–802
10. Shapiro RA, Schubert CJ, Siegel RM. *Neisseria gonorrhoea* infections in girls younger than 12 years of age evaluated for vaginitis. *Pediatrics.* 1999;104:e72. Available at: <http://pediatrics.aappublications.org/cgi/content/full/104/6/e72>
11. Bell TA, Stamm WE, Wang SP, Kuo CC, Holmes KK, Grayston JT. Chronic *Chlamydia trachomatis* infections in infants. *JAMA.* 1992;15;267:400–402
12. Centers for Disease Control and Prevention. Sexually transmitted diseases treatment guidelines 2002. *MMWR Morb Mortal Wkly Rep.* 2002;51(RR-6)
13. Kellogg N, American Academy of Pediatrics Committee on Child Abuse and Neglect. The evaluation of sexual abuse in children. *Pediatrics.* 2005;116:506–512
14. Nour NM. Female genital cutting: clinical and cultural guidelines. *Obstet Gynecol Surv.* 2004;59:272–279
15. Kaplowitz PB, Oberfield SE. Reexamination of the age limit for defining when puberty is precocious in girls in the United States: implications for evaluation and treatment. Drug and Therapeutics and Executive Committees of the Lawson Wilkins Pediatric Endocrine Society. *Pediatrics.* 1999;104:936–941

PIR Quiz

Quiz also available online at www.pedsinreview.org.

6. Which of the following physical examination findings in a prepubescent girl is *most* suggestive of sexual abuse?
 - A. Bruising around the inner thighs.
 - B. Hymenal diameter of 5 mm.
 - C. Hymenal tag.
 - D. Thin white vaginal discharge.
 - E. Urethral dilatation.

7. A 3-year-old girl presents with a history of a dark staining in her underpants of 2 weeks' duration. The mother has noted no apparent itching or pain, and there is no known history of trauma. The physical examination reveals a foul-smelling, brownish discharge at the vaginal introitus. There is no erythema or excoriation of the vulva. Of the following, the *most* likely diagnosis is:
 - A. *Candida* infection.
 - B. Gonococcal vulvovaginitis.
 - C. Pinworm infection.
 - D. Urethral prolapse.
 - E. Vaginal foreign body.

8. The parents of an 18-month-old girl who was adopted from Sudan ask you to examine her because they suspect that she underwent female circumcision just before they adopted her. Which of the following is true regarding this procedure?
 - A. If she had the procedure, she will be unable to enjoy sexual activity as an adult.
 - B. It is unlikely that she had the procedure because it no longer is performed in African countries.
 - C. Most girls who have had the procedure have dramatic abnormalities of the genitalia on examination.
 - D. She should be evaluated for human immunodeficiency virus, hepatitis B, and hepatitis C, even if the examination reveals normal findings.
 - E. The presence of clitoral tissue on examination excludes the possibility that the procedure was performed.

9. A 5-year-old girl presents with a 5-day history of vaginal discharge. She denies dysuria and itching. She has had some mild diarrhea. Physical examination reveals a well-appearing girl who has no unusual findings on abdominal examination. There is mild vulvar erythema, and a yellow discharge is noted at the vaginal introitus. The urethra appears normal. Of the following, the *most* appropriate management of this patient is to:
 - A. Insert a catheter into the vagina and irrigate with normal saline.
 - B. Obtain a culture for enteric pathogens, *Haemophilus influenzae*, group A *Streptococcus*, and *Neisseria gonorrhoeae* and start antibiotics pending culture results.
 - C. Prescribe sitz baths and arrange for follow-up in 2 weeks.
 - D. Refer her to a pediatric gynecologist for an examination under anesthesia.
 - E. Treat her for presumed pinworm infection.

Common Gynecologic Problems in Prepubertal Girls

Naomi F. Sugar and Elinor A. Graham

Pediatrics in Review 2006;27;213

DOI: 10.1542/pir.27-6-213

Updated Information & Services

including high resolution figures, can be found at:
<http://pedsinreview.aappublications.org/content/27/6/213>

References

This article cites 14 articles, 6 of which you can access for free at:
<http://pedsinreview.aappublications.org/content/27/6/213#BIBL>

Subspecialty Collections

This article, along with others on similar topics, appears in the following collection(s):
Adolescent Medicine/Gynecology
http://pedsinreview.aappublications.org/cgi/collection/adolescent_medicine_gynecology
Growth and Development
http://pedsinreview.aappublications.org/cgi/collection/growth_development

Permissions & Licensing

Information about reproducing this article in parts (figures, tables) or in its entirety can be found online at:
</site/misc/Permissions.xhtml>

Reprints

Information about ordering reprints can be found online:
</site/misc/reprints.xhtml>

American Academy of Pediatrics

DEDICATED TO THE HEALTH OF ALL CHILDREN™

