

PediatricsⁱⁿReview[®]

Enterovirus Infections

Theoklis Zaoutis and Joel D. Klein

Pediatrics in Review 1998;19;183

DOI: 10.1542/pir.19-6-183

The online version of this article, along with updated information and services, is located on the
World Wide Web at:

<http://pedsinreview.aappublications.org/content/19/6/183>

Pediatrics in Review is the official journal of the American Academy of Pediatrics. A monthly publication, it has been published continuously since 1979. Pediatrics in Review is owned, published, and trademarked by the American Academy of Pediatrics, 141 Northwest Point Boulevard, Elk Grove Village, Illinois, 60007. Copyright © 1998 by the American Academy of Pediatrics. All rights reserved. Print ISSN: 0191-9601.

American Academy of Pediatrics

DEDICATED TO THE HEALTH OF ALL CHILDREN™



Enterovirus Infections

Theoklis Zaoutis, MD* and Joel D. Klein, MD†

IMPORTANT POINTS

1. Enteroviral infections occur primarily during the summer and fall months; the fecal-oral route is the most common mode of transmission.
2. New polio vaccination regimens have been developed to reduce or eliminate the incidence of vaccine-associated paralytic poliomyelitis.
3. Neonates infected with enteroviruses can present with a sepsis-like clinical picture indistinguishable from bacterial sepsis.
4. Herpangina and hand-foot-mouth disease often can be distinguished from herpes simplex and varicella infections by the distribution of the rash and the severity of constitutional symptoms.
5. Enteroviruses are the most common cause of aseptic meningitis, which usually presents with fever, meningeal signs, cerebrospinal fluid pleocytosis (<500 white blood cells/mm³), and normal levels of cerebrospinal fluid glucose and protein.

Introduction

Enteroviruses (polioviruses, coxsackieviruses, echoviruses) are among the most common and significant causes of infectious illness in infants and children. They are associated with a broad spectrum of clinical syndromes, including aseptic meningitis, herpangina, hand-foot-mouth disease, conjunctivitis, pleurodynia, myopericarditis, poliomyelitis, various exanthems, and nonspecific febrile illness. In the neonate, enteroviral infection can cause a sepsis-like picture or meningoencephalitis, either of which can be severe. Newer technologies such as polymerase chain reaction (PCR) may provide rapid and sensitive testing methods for diagnosis of enteroviral infections, which may expand the list of diseases attributable to this group of pathogens. Although treatment of enteroviral infections remains unsatisfactory, immunization against poliovirus has been remarkably successful, and new immunization regimens using live and killed virus vaccines have been developed. A role has been postulated for enteroviruses in the pathogenesis of diabetes mellitus.

*Resident, Department of Pediatrics.

†Chief, Division of Pediatric Infectious Diseases, duPont Hospital for Children, Wilmington, DE; Jefferson Medical College, Philadelphia, PA.

History

In 1920, soon-to-be president Franklin Delano Roosevelt developed a febrile illness during his summer vacation that was followed by paralysis. Although this is one of the most publicly recognized cases of paralytic poliomyelitis, polio has been described as early as 1580 B.C. An Egyptian stone tablet shows a young priest who has a withered, shortened leg, the characteristic deformity of poliomyelitis. The virus was not isolated until 1949 when John Enders grew it in tissue culture. Following the isolation and identification of this prototypic enterovirus, other members of the enteroviral family were studied and their properties elucidated.

Characteristics of Enteroviruses

The enteroviruses are a subgroup of single-stranded RNA, non-enveloped viruses belonging to the Picornaviridae family (pico=small, RNA=ribonucleic acid). They include the polioviruses, coxsackieviruses, echoviruses (echo=enteric cytopathogenic human orphan), and unclassified enteroviruses. Early classification of enteroviruses involved groupings based on cytopathologic effect in tissue culture. Newly discovered enteroviruses are now simply assigned enterovirus type numbers. The enteroviruses

currently recognized to infect humans are outlined in Table 1. Enterovirus 72 is hepatitis A virus, which differs from the other enteroviruses by having only one serotype and replicating only in liver cells. It will not be included in this review.

The virion consists of an icosahedron-shaped protein capsid and an RNA core. Although the capsid proteins determine antigenicity, there are no significant antigens common to all members of this group of viruses. The virus can withstand the acidic pH of the human gastrointestinal tract and can survive at room temperature for several days. These features enable the fecal-oral mode of transmission. Most enteroviruses can grow in primate (human or non-human) cell cultures, exhibiting cytopathic effect in 3 to 7 days.

Epidemiology

Enteroviruses are commonly referred to as "summer viruses" because resulting infections occur primarily during the warmer, summer months (May through October) in temperate northern hemisphere climates such as in the United States. In tropical climates, enteroviral infection is seen all year without seasonal variation.

Humans are the only known natural hosts for enteroviruses.

TABLE 1.
Human Enteroviruses

GROUP	SEROTYPES
Poliovirus	1–3
Coxsackievirus group A	1–22, 24
Coxsackievirus group B	1–6
Echovirus	1–9, 11–27, 29–33
Enterovirus	68–72*

*Hepatitis A virus was enterovirus type 72, but recently has been reclassified as a Heparnavirus.

INFECTIOUS DISEASE Enterovirus Infections

The fecal-oral route is the most common mode of transmission, but oral-oral and respiratory spread also are possible. Risk factors for infection include poor sanitation, crowded living conditions, and low socioeconomic class. Children younger than 5 years of age are the most susceptible to infection, due in part to a lack of prior immunity and to the poor hygienic habits associated with this age group.

Sixty-eight enteroviral serotypes have been identified, but most infections are caused by a small number of these. During annual epidemics of clinical disease, certain serotypes predominate. In the past 25 years, approximately 15 serotypes have been responsible for the majority of infections and include echoviruses 4, 6, 9, 11, and 30; coxsackieviruses A9, A16, and B2 through B5; and enteroviruses 70 and 71. A given serotype may decrease in prevalence following an epidemic only to re-emerge in subsequent outbreaks, when a new group of susceptible hosts becomes available.

The pattern of enteroviral epidemics occurring each season has

not included the polioviruses since the use of vaccination virtually eliminated paralytic poliomyelitis from developed nations.

Pathogenesis

The incubation period for most enteroviral infections ranges from 3 to 10 days. The virus enters the host via the oral cavity and/or respiratory tract, then invades and replicates in the upper respiratory tract and small intestine, with a predilection for lymphoid tissues in these regions (Peyer patches, mesenteric nodes, tonsils, and cervical nodes). Virus then enters the bloodstream, resulting in a minor viremia and dissemination to a variety of target organs, including the central nervous system (CNS), heart, liver, pancreas, adrenal glands, skin, and mucous membranes. A major viremia results from viral replication at and dissemination from these secondary sites, which provide additional opportunities for seeding the CNS (Table 2). The minor and major viremia may correlate with the biphasic appearance of fever and symptoms com-

monly described in enteroviral infections (Fig 1).

Viremia is the most common source of CNS infection, with some enteroviral serotypes exhibiting increased neurotropism or neurovirulence. These include all three serotypes of poliovirus, numerous echovirus strains, and coxsackieviruses B3 through B5. In paralytic

TABLE 2. Pathogenesis of Enteroviruses

• Entry of virus via oral and/or respiratory route
• Viral replication in regional lymph nodes of upper respiratory and gastrointestinal tracts
• Minor viremia; onset of symptoms
• Viral replication in heart, liver, skin, and other organs
• Major viremia with secondary seeding of central nervous system

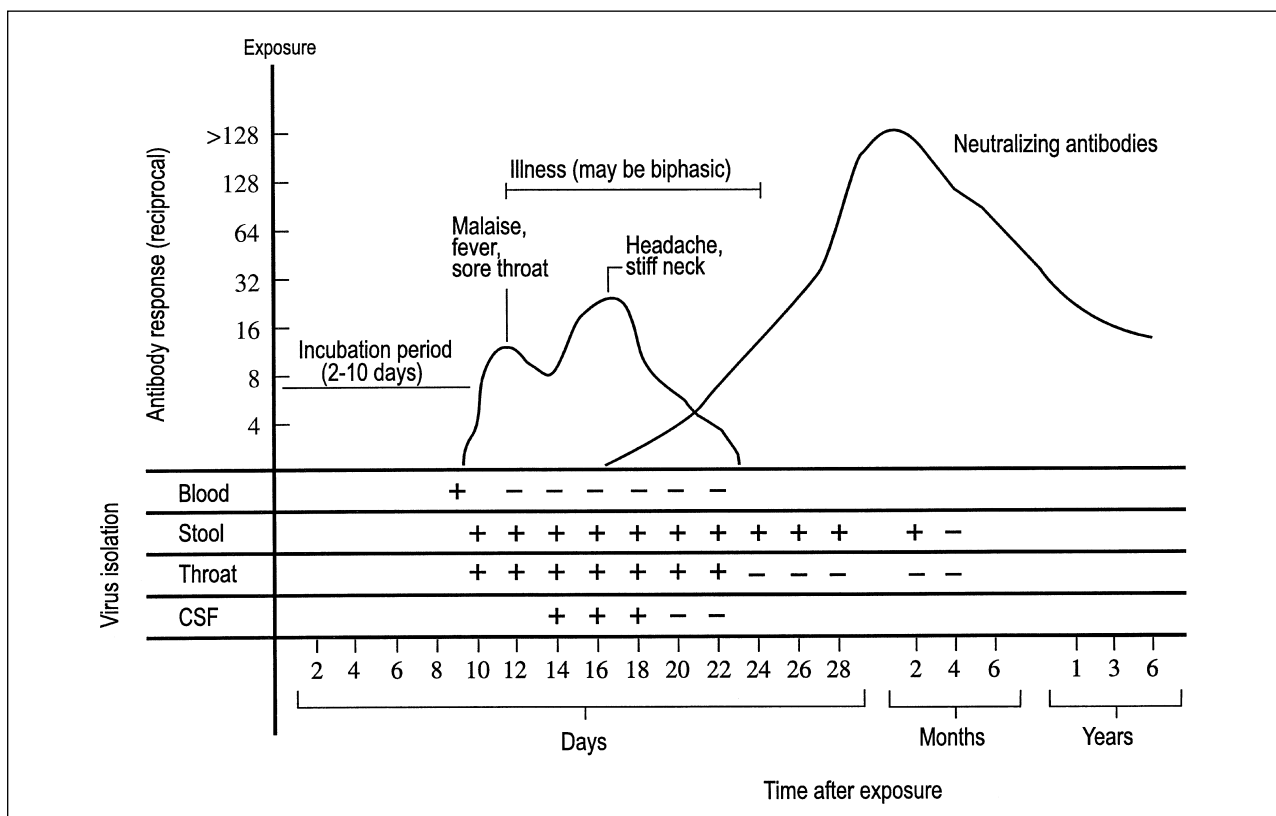


FIGURE 1. Clinical course, viral isolation, and antibody response in enteroviral infection. Reproduced with permission from Sherris J, ed. *Medical Microbiology. An Introduction to Infectious Diseases*. New York, NY: Simon and Schuster, Inc; 1984.

polio infection, the virus replicates in the motor neurons in the anterior horn of the spinal cord and brainstem, leading to death of the neuronal cells and paralysis of the innervated muscles.

The immune response in enteroviral infections involves an early immunoglobulin M (IgM) antibody response at 7 to 10 days, followed by a rise in IgG and intestinal IgA neutralizing antibodies. There is relative immunity to reinfection with the same serotype, but if reinfection does occur, the symptoms are ameliorated and the illness may be subclinical.

Clinical Presentations of Infection With Nonpolio Enteroviruses

Nonpolio enteroviruses are estimated to cause 10 to 15 million symptomatic infections in the United States annually. They cause a wide spectrum of disease that can involve almost any organ system (Table 3). Disease severity can range from life-threatening with significant morbidity to mild or subclinical.

It is believed that approximately 50% of nonpolio enterovirus infections are asymptomatic. The more common syndromes include nonspecific febrile illness, aseptic meningitis, herpangina, hand-foot-mouth syndrome, and exanthems. The clinical manifestations of infection in the neonate can be distinct and will be discussed separately.

NONSPECIFIC FEBRILE ILLNESS

The most common clinical presentation of nonpolio enterovirus infection is a nonspecific febrile illness. Typically, fever develops suddenly, without a prodrome, and temperatures range from 38.5° to 40°C (101° to 104°F) and last for an average of 3 days. Occasionally, a biphasic pattern of symptoms can be seen, with an initial fever for 1 day, followed by 2 to 3 days of normal temperatures and recurrence of fever for an additional 2 to 4 days. Accompanying symptoms are nonspecific and include malaise, myalgia, headache, and sore throat, as well as gastrointestinal symptoms of nausea, vomiting, mild abdominal discomfort, and mildly loose stools.

Findings on the physical examination are usually unremarkable, but mild conjunctivitis, lymphadenitis, or pharyngeal erythema may be present. If a white blood cell count is obtained, there is usually little to no elevation and no shift in the differential. Knowledge that the fever can last for up to 1 week may prevent unnecessary diagnostic evaluations and ease parental fears.

ASEPTIC MENINGITIS

Nonpolio enteroviruses are the leading causes of aseptic meningitis, accounting for 80% to 90% of all cases from which an etiologic agent is identified. The most common enterovirus types associated with aseptic meningitis are coxsackievirus B5 and echoviruses 4, 6, 9, and 11. These have occurred in epidemic outbreaks as well as sporadic cases.

The initial presentation is similar to that of nonspecific febrile illness. Commonly, a biphasic pattern of symptoms is seen, with signs of CNS involvement developing in addition to recurrence of fever. Evidence for meningeal irritation commonly includes headache and

TABLE 3. Clinical Syndromes and Associated Enteroviruses

SYNDROME	PREDOMINANT VIRUS	CLINICAL FEATURES
Nonspecific febrile illness	All types	Febrile illness (occasionally biphasic), with nonspecific upper respiratory and gastrointestinal tract symptoms
Aseptic meningitis	Echovirus and group B coxsackieviruses	Fever, meningeal signs with mild cerebrospinal (CSF) pleocytosis, usually normal CSF glucose and protein, and absence of bacteria
Herpangina	Group A coxsackieviruses	Fever, painful oral vesicles on tonsils and posterior pharynx
Hand-foot-mouth disease	Coxsackievirus A16	Fever, vesicles on buccal mucosa and tongue and on interdigital surfaces of hands and feet
Nonspecific exanthem	Echoviruses	Variable rash (usually rubelliform but may be petechial or vesicular), +/- fever
Pleurodynia	Coxsackievirus B3, B5	Uncommon, epidemic, fever, and severe muscle pain of chest and abdomen
Carditis	Group B coxsackievirus	Uncommon, myocarditis/pericarditis, which can present with heart failure or dysrhythmia
Acute hemorrhagic conjunctivitis	Enterovirus 70	Epidemic cause of conjunctivitis with lid swelling, subconjunctival hemorrhage, and eye pain without systemic symptoms
Neonatal disease	Group B coxsackieviruses and echoviruses	Sepsis-like picture, meningoencephalitis, hepatitis, myocarditis

photophobia, with 50% of children older than 1 to 2 years of age also developing nuchal rigidity. Approximately one third of these older children will have a positive Kernig and/or Brudzinski sign. Children younger than 1 year of age usually have no specific meningeal signs, but exhibit increased irritability. Rash is often present and is usually nonspecific. However, on occasion it is petechial and may be confused with the rash of meningococemia.

Examination of the cerebrospinal fluid (CSF) reveals a mildly elevated white blood cell count that typically is less than 500/mm³ but can be as high as 2,000/mm³. In the first 1 to 2 days of the illness, polymorphonuclear cells predominate, but they are replaced rapidly by mononuclear cells. Because bacterial meningitis usually produces a persistent granulocytosis in the CSF, sequential lumbar punctures can be useful in differentiating bacterial from viral infection. The CSF glucose level tends to be normal, but it has been reported to be low in some patients, and the CSF protein concentration may be normal or mildly elevated (80 to 100 mg/dL).

The differential diagnosis for aseptic meningitis is extremely broad and includes the tick-borne illnesses (ie, Rocky Mountain spotted fever, Lyme disease, and ehrlichiosis) as well as arbovirus infections. These all occur more commonly during the summer/autumn months, which corresponds to the peak season for enteroviral infection. The distribution and character of the rash and blood count findings may help distinguish these different entities. Partially treated bacterial meningitis may present with similar clinical and CSF findings; this possibility should be considered in every patient presenting with aseptic meningitis. The presence of other identifiable enteroviral syndromes in the community, such as herpangina and hand-foot-mouth disease, can be useful in diagnosis because outbreaks tend to be epidemic and seasonal.

The course of enteroviral meningitis usually is self-limited and benign, but there has been ongoing debate about the occurrence of long-

term sequelae. Recent large studies have shown that there are no long-term neurologic, cognitive, or developmental abnormalities from this infection in older children. However, several investigations have documented that 10% of children younger than 3 months of age who have aseptic meningitis may suffer long-term sequelae, especially speech and language delay.

CNS infection by nonpolio enteroviruses less commonly is manifested as encephalitis, which is often severe and, unlike meningitis, can result in long-term sequelae. The encephalitis is typically global, which can differentiate it from the focal presentation often seen with herpes simplex encephalitis.

HERPANGINA

Herpangina is an enanthemous (mucous membrane) disease characterized by a painful vesicular eruption of the oral mucosa associated with fever, sore throat, and pain on swallowing. It is seen most commonly in children ages 3 to 10 years. Group A coxsackieviruses are the most common etiologic agents, but group B coxsackieviruses and echoviruses also have been isolated from patients.

Fever, usually mild, develops suddenly, but higher temperatures up to 41°C (105.8°F) can be seen, particularly in younger patients. Nonspecific early symptoms may include headache, vomiting, and myalgia. Sore throat and pain with swallowing are the most prominent symptoms and precede the characteristic enanthem by approximately 1 day. The enanthem consists of punctate macules that vesiculate and ulcerate. The vesicles and ulcers are surrounded by an erythematous ring and are found on the anterior tonsillar pillars, soft palate, and posterior pharynx. There are typically two to six lesions, but there can be as many as 12 to 16. The posterior oropharynx usually is minimally erythematous. Herpangina is self-limited, and symptoms resolve within 1 week. Young children are at risk for dehydration because of refusal to eat or drink.

Lymphonodular pharyngitis, a variant of herpangina, presents similarly but differs in the appearance of

the oral lesions, which are tiny, firm, white nodules (packed with lymphocytes) in the same distribution.

The differential diagnosis for herpangina is discussed in the next section.

HAND-FOOT-MOUTH (HFM) DISEASE

HFM disease is characterized clinically by a vesicular eruption on the hands and feet and in the oral cavity. Toddlers and school-age children are affected most commonly. Coxsackievirus A16 is the primary etiologic agent, but other enteroviruses have been implicated as well.

Patients present with fever of 38° to 39°C (100.4° to 102.2°F) that lasts 1 to 2 days, sore mouth or throat, and the characteristic exanthem/enanthem. The oral vesicles usually are located on the buccal mucosa and tongue and are only mildly painful. They are surrounded by erythematous rings and eventually ulcerate (Fig 2). The exanthem involves vesicles on the palms, soles, and interdigital surfaces of the hands and feet (Fig 3). Less commonly, lesions (nonvesicular) can be seen on the buttocks, proximal extremi-

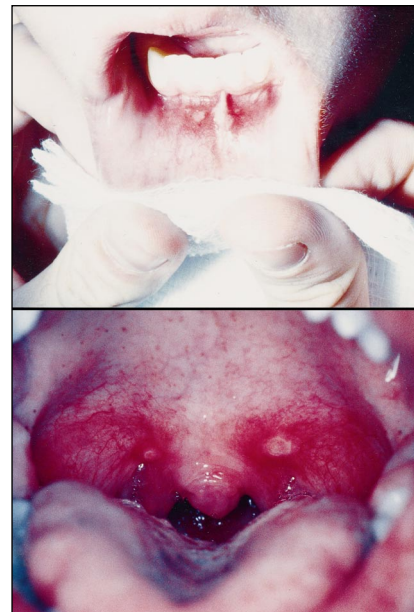

FIGURE 2. Characteristic distribution of oral ulcers in hand-foot-mouth disease (top); lesions occasionally occur on posterior soft palate (bottom). Reproduced with permission from Slide Atlas of Pediatric Physical Diagnosis. New York, NY: Gower Medical Publishing Ltd; 1987.

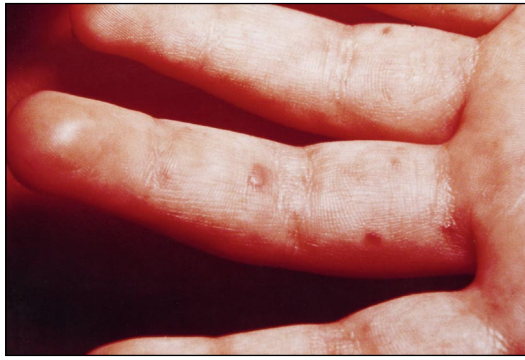

FIGURE 3. Characteristic distribution and appearance of hand-foot-mouth disease lesions on the hand. Reproduced with permission from Slide Atlas of Pediatric Physical Diagnosis. New York, NY: Gower Medical Publishing Ltd; 1987.

ties, and genitalia. Most children recover within 1 week.

The differential diagnosis for HFM disease includes infection by herpes simplex or varicella-zoster virus, herpangina, and aphthous stomatitis. In contrast to HFM, varicella lesions are located more centrally, are more extensive, and usually spare the palms and soles. Additionally, resolution of varicella lesions involves crusting, whereas HFM vesicles resolve by resorption of fluid. In herpetic gingivostomatitis, patients usually appear more ill, may have gingival erythema or bleeding, present with higher temperatures, and exhibit significant cervical lymphadenopathy and lesions confined to the oral cavity without extremity involvement. These findings may help distinguish herpetic stomatitis from HFM. Herpangina also may resemble HFM, but the herpangina oral lesions usually are located in the posterior aspects of the pharynx; the extremities are spared. Aphthous stomatitis is characterized by larger, ulcerative lesions of the lips, tongue, and buccal mucosa that are exquisitely painful. It is seen most commonly in older children and adults, has multiple recurrences, and generally is not associated with constitutional symptoms.

NONSPECIFIC EXANTHEM

Nonpolio enteroviruses are the leading cause of exanthems in children during the summer and fall months. The most common serotype causing exanthem is echovirus 9. The classic

enteroviral exanthem consists of a pink, macular, blanching, rubelliform rash. Unlike rubella, this rash usually is not associated with adenopathy. Less commonly, the rash can appear maculopapular, vesicular, roseola-like, urticarial, or petechial. The rash may be the sole manifestation of infection or may present in association with febrile illness or aseptic meningitis. It also can be seen after fever disappears, thus mimicking

roseola. Enteroviral exanthems are seen most commonly in children younger than 5 years of age and decrease in prevalence with age. The rash is self-limited and disappears in 3 to 5 days.

ADDITIONAL CLINICAL MANIFESTATIONS

Nonpolio enterovirus can cause a wide range of symptoms that are clinically indistinguishable from those of other viral syndromes. These include upper or lower respiratory tract infections, arthritis, orchitis, nephritis, and gastroenteritis. Of note, gastrointestinal symptoms such as vomiting, diarrhea, and abdominal pain are common in children who have enteroviral infections, but rarely are the sole complaints.

Other Relevant Syndromes

Several illnesses, although relatively uncommon, are classically associated with enteroviral infection.

PLEURODYNIA (BORNHOLM DISEASE)

Pleurodynia or epidemic myalgia is characterized by an acute onset of severe muscular pain in the chest and abdomen accompanied by fever. Coxsackieviruses B3 and B5 are the major causes of epidemic disease; rare sporadic cases have been described with other nonpolio enteroviruses.

The muscular pain is sharp and spasmodic, with episodes typically lasting 15 to 30 minutes, although

they can last up to several hours. During spasms patients may develop signs of respiratory distress or appear shock-like with diaphoresis and pallor. Pain localized to the abdomen in young children may falsely suggest intussusception or appendicitis. The illness usually lasts 1 to 2 days, but frequently a biphasic pattern is seen, with recurrences possible several weeks after the initial episode. Associated signs and symptoms include anorexia, headache, nausea, and vomiting. The affected muscles are tender to palpation, and occasionally a pleural friction rub is heard on auscultation. In contrast to many other enteroviral syndromes, pleurodynia is more common in older children and adolescents.

MYOCARDITIS/PERICARDITIS

Enteroviral myocarditis and/or pericarditis is associated with group B coxsackievirus (B5 most commonly) in up to 50% of cases. Patients present with fatigue, dyspnea on exertion, or more fulminant symptoms of heart failure or dysrhythmia. Cardiac involvement is usually self-limited, with complete recovery, but overall mortality associated with myocarditis is significant.

Recent evidence indicates that coxsackievirus cardiac infection can be chronic. Viral-specific IgM antibodies have been found in patients who have chronic pericarditis, and enteroviral genetic material has been detected from biopsy specimens of patients who have dilated cardiomyopathy. Several studies also have described an association between group B coxsackievirus infection and myocardial infarction in adults.

ACUTE HEMORRHAGIC CONJUNCTIVITIS (AHC)

This explosive epidemic conjunctivitis, first described in 1969 in Africa and Asia, is now found worldwide. It is more common in tropical and densely populated regions. The majority of outbreaks have been caused by enterovirus serotype 70, but recently coxsackievirus A24 has been isolated during outbreaks. AHC is characterized by sudden onset of severe eye pain, photophobia, and blurred vision. Subconjunctival hemorrhages, erythema, edema

of the lids, eye discharge, and preauricular lymphadenopathy are seen. Secondary bacterial infection is common. Systemic symptoms are usually absent, and recovery occurs within 7 to 10 days. Spread is by the eye-hand-fomite route in contrast to the fecal-oral route seen with most enteroviral infections. Overall, it is more common in adults, but it also does affect school-age children.

Neonatal Disease

Neonates infected with nonpolio enteroviruses are at high risk for developing significant illness, including a sepsis-like condition, meningoencephalitis, myocarditis, and/or hepatitis. Echoviruses and group B coxsackieviruses account

and, at times, fatal disease manifests as pneumonitis, hepatitis, disseminated intravascular coagulation, and meningoencephalitis. In a recent study profiling enterovirus infection in the first 2 weeks of life, 17% of infected infants developed severe, multisystem disease. Although 100% survival was reported, other studies have indicated that CNS deficits may be a long-term sequela.

Special Clinical Considerations

Enteroviral infections also pose significant risk to children who have defects in B-lymphocyte function, the most common of which is X-linked agammaglobulinemia. Unlike other viruses that are com-

from virus shed from recent OPV recipients.

Clinical Manifestations of Infection With Poliovirus

Most infections caused by poliovirus are asymptomatic or subclinical; only about 1% become clinically apparent. Of the three serotypes of poliovirus, type 1 causes the majority of epidemics. Three clinical syndromes are attributed to poliovirus infection—abortive poliomyelitis, aseptic meningitis, and paralytic poliomyelitis. Abortive poliomyelitis is characterized by a nonspecific febrile illness that includes headache, sore throat, and no CNS involvement. These symptoms last 2 to 3 days before resolving. Poliovirus infection also can be manifested as aseptic meningitis, indistinguishable from the same syndrome caused by other enteroviruses.

Paralytic poliomyelitis begins with a minor febrile illness that is followed by a short asymptomatic period of 2 to 3 days. A sudden onset of asymmetric flaccid paralysis with no significant sensory loss is the characteristic finding of paralytic disease. Maximum neurologic damage occurs within a few days. Motor neuron damage is permanent, but some recovery results from other nerve cells taking over some of the function. The most substantial portion of functional recovery occurs within the first 6 months; little or no recovery is noted after 1 year. Bulbar poliomyelitis affects the sensory, speech, and cardiorespiratory centers of the brainstem and can cause death by paralysis of the respiratory muscles.

Emerging Roles Of Enteroviruses

The role of enteroviruses, specifically group B coxsackieviruses, in the pathogenesis of type 1 diabetes mellitus has been studied extensively. A growing amount of epidemiologic and experimental research suggests a strong association. For example, new-onset type 1 diabetes mellitus occurs in clusters, with a seasonal pattern that peaks 1 to 2 months after the enteroviral season.

Infants younger than 10 days of age are at higher risk for severe enterovirus infections because of their relative inability to mount a significant immune response.

for the majority of neonatal enterovirus infections. Infection is usually acquired during birth or by postnatal contact with an infected caretaker. Transplacental transmission is possible but less likely. Nosocomial transmission has accounted for multiple outbreaks in nurseries.

Infection occurs in 20% to 50% of infants in whom there is a maternal history of illness in the week preceding delivery. The severity of the neonatal illness is related to the severity of maternal illness at the time of delivery as well as to the age of the infant at onset of infection. Infants younger than 10 days of age are at higher risk for severe disease because of their relative inability to mount a significant immune response and their lack of serotype-specific maternal antibody. Asymptomatic infection is common, but one study documented that up to 20% of infected infants developed symptomatic disease during an enterovirus season. Presenting symptoms include fever, irritability, lethargy, poor feeding, hypoperfusion, abdominal distention, and jaundice. The sepsis-like clinical picture often is indistinguishable from bacterial sepsis. Fulminant

bated by cellular immune mechanisms, enteroviruses are eliminated from the host by humoral immune mechanisms. An intact B-cell response is believed to be necessary to block viral entry into the CNS.

Children who have agammaglobulinemia may develop chronic enteroviral infection, most commonly meningoencephalitis. Patients present with headache, lethargy, seizures, motor dysfunction, and altered sensorium. Symptoms may wax and wane for years, but there is an overall progressive deterioration in CNS function. Pleocytosis and elevation of protein concentration persist in CSF, and virus can be recovered from the CSF for months to years. A late manifestation of chronic enteroviral infection is a dermatomyositis-like syndrome in which virus is present in many body tissues. Infection is fatal in most children who are immunodeficient. Echovirus 11 has been the most common cause of chronic infection, but cases caused by other echoviruses and coxsackieviruses have been reported. Children who have agammaglobulinemia are at risk for developing paralytic poliomyelitis from oral polio vaccine (OPV) or

Numerous studies have investigated the presence of IgM antibodies to coxsackieviruses in patients who have type 1 diabetes and controls; most have demonstrated an increased prevalence of the antibodies in patients compared with controls. Coxsackieviruses have been isolated from pancreatic tissue of children who have died of diabetic ketoacidosis, and injury to pancreatic beta cells by coxsackievirus has been duplicated in cell culture models. The process by which viral infection could cause type 1 diabetes mellitus is not clear. Among the theories are an autoimmune response due to cross-reacting antigens found in the pancreas and the virus, direct viral injury, genetic predisposition, or a combination of these and other yet unknown factors.

Diagnosis

Enteroviral infection usually is diagnosed clinically without isolation and identification of the specific virus. Factors that aid in diagnosis include seasonality, knowledge of exposure, and characteristic constellation of physical findings and symptoms. In certain clinical situations, such as meningitis or neonatal disease, isolation and/or identification of the virus may be indicated.

Laboratory methods for diagnosing enterovirus infections include cell culture, serology, and newly developed PCR techniques. The gold standard for diagnosis has been isolation of enterovirus in cell culture. Virus can be isolated from stool, throat, blood, and CSF of infected individuals, but most clinical specimens are CSF. Isolation from blood is not common because viremia is usually undetectable by the time symptoms appear. Virus can be isolated from the throat for 2 days to approximately 2 weeks after infection. Isolation of virus from stool must be interpreted with caution because asymptomatic individuals can shed virus for up to 4 to 8 weeks.

Serologic diagnosis is made by demonstrating a fourfold or greater increase in neutralizing antibody titers between paired acute and convalescent serum samples. Quantitative interpretation of a single serum

sample is not useful because there is a wide range of titers to different serotypes in healthy individuals. The more than 60 antigenically different serotypes that have no common group antigens makes serologic techniques both cumbersome and impractical.

The most promising development in diagnostic techniques for enteroviral infections is PCR. The genetic probe is directed against a region that is conserved among almost all enteroviral serotypes. One such PCR test has been evaluated against 66 serotypes and found to detect 60 of them. The PCR technique has been tested almost exclusively in CSF samples and found to be more sensitive than cell culture and 100% specific. Colorimetric assays using

was associated with faster cessation of viremia and viruria (commonly seen in neonatal infection). The efficacy of IVIG in children who have agammaglobulinemia has been inconsistent.

Prophylaxis

The only enterovirus for which a vaccine is available is poliovirus. Use of poliovirus vaccines has eradicated polio from the Western Hemisphere and dramatically decreased the incidence worldwide. The first poliovirus vaccine, developed by Salk in 1955, was an inactivated poliovirus vaccine (IPV). In 1962, Sabin developed an oral, live attenuated poliovirus vaccine (OPV) that contains all three serotypes.

Enteroviral infection usually is diagnosed clinically, using seasonality, exposure, and characteristic physical findings and symptoms.

PCR methods that can be performed in 5 hours have been shown to be 90% sensitive and 97% specific. PCR testing of serum and urine samples from neonates in whom infection was suspected was twice as sensitive as cell culture and 100% specific. PCR technology soon may allow sensitive and rapid diagnosis.

Treatment

No effective antiviral therapy currently is available for enteroviral infections; treatment is symptomatic and supportive. Corticosteroids have been of some benefit in the treatment of myocarditis, but their use is generally not recommended because administration in experimental animal models has had deleterious effects.

Because clearance of enteroviral infections depends on humoral immune factors, intravenous immune globulin (IVIG) has been used in neonates and immunodeficient children. Most available data on successful outcomes are from anecdotal reports. A recent, small, randomized study in infected newborns revealed that administration of IVIG containing high neutralizing titers to the patient's specific viral isolate

Both vaccines are highly immunogenic, with greater than 95% seroconversion rates among recipients.

After its introduction, OPV was adopted rapidly worldwide as the vaccine of choice. Its advantages over IPV include ease of administration, secondary immunization of vaccinee contacts, and stimulation of local immunity in the gastrointestinal tract. Because the pathogenesis of polio infection depends on intestinal entry, high levels of neutralizing antibodies locally (ie, in intestinal mucosa) are optimal for protection. With OPV, live virus replicates in the small intestine, thereby inducing high titers of secretory IgA at this location. In addition, the presence of intestinal immunity may help prevent spread of wild poliovirus within an incompletely immunized population. This is believed to occur by binding of the wild poliovirus within the intestines of vaccinated individuals. As previously mentioned, secondary immunization (herd immunity) may represent an additional advantage of OPV. It has been estimated that 10% to 20% of unvaccinated children in inner cities are effectively vaccinated by contact with virus shed by vaccine recipients.

OPV in developing countries is less immunogenic, as measured by seroconversion rates. Several factors are probably responsible for this phenomenon, including inadequate refrigeration of the vaccine, poor nutrition among recipients, and coinfection of the gastrointestinal tract with other enteroviruses, all of which may cause diminished immunogenicity.

The primary risk associated with OPV administration is development of vaccine-associated paralytic poliomyelitis (VAPP). The last case of wild-type poliomyelitis in the United States was seen in 1979. Since then, there have been 8 to 10 cases per year of paralytic poliomyelitis, all attributed to the live virus vaccine. This corresponds to approximately 4 cases per 10 million doses of vaccine administered. The greatest risk for VAPP (>75% of cases) is seen after the initial dose of OPV, with about 1 in 700,000 American children or contacts developing paralytic disease. Vaccine virus can undergo reverse mutation in the intestinal tract of vaccinees, and these revertant strains have a selective advantage for replication in the intestine and may possess increased virulence. Poliovirus serotype 3 accounts for 92% of VAPP because it is genetically more unstable, followed by serotype 2 and then 1.

Because OPV is a live virus vaccine and live virus is excreted by vaccinees, it never should be administered to immunocompromised recipients or to those living in households that contain immunocompromised people. This includes those who have human immunodeficiency virus infection, lymphoma, leukemia, solid tumors, abnormal immunoglobulin synthesis, or immunosuppression due to medications prescribed for other diseases. IPV should be administered in these situations because there is no live virus and, therefore, no risk of VAPP. It is theoretically prudent not to vaccinate pregnant women, but if immediate protection against polio is required, OPV, not IPV, is recommended. Breastfeeding, concurrent antimicrobial use, or diarrhea are not contraindications to OPV administration.

The initial IPV was replaced in the 1980s by an enhanced potency inactivated poliovirus vaccine (eIPV), which exhibits even higher seroconversion rates with fewer doses. It has been used successfully in several European countries (Finland, Netherlands, Norway, and Sweden) as the sole mode of polio immunization. No serious adverse reactions have been reported, although it contains trace amounts of streptomycin and neomycin and, therefore, hypersensitivity reactions are a possibility in patients who are sensitive to these antibiotics.

Prior to 1996, the OPV regimen was employed in routine childhood immunization. However, with the eradication of wild-type polio from the United States and many other developed countries and the ongoing concern about the small number of VAPP each year, other options for dosing were established. The American Academy of Pediatrics (AAP)

currently recommends any one of three polio vaccination schedules: an all-OPV regimen, a mixed eIPV/OPV regimen, or an all-eIPV regimen (Table 4). The Centers for Disease Control and Prevention and the Advisory Committee for Immunization Practices recommend the mixed schedule of eIPV followed by OPV, which maintains the benefits of intestinal and herd immunity associated with OPV while reducing the risk of VAPP by initially immunizing with eIPV.

Recent studies comparing all-OPV, all-eIPV, and eIPV/OPV combinations reveal excellent systemic immunity and nasopharyngeal neutralizing antibodies with all regimens, but higher nasopharyngeal IgA titers with the all-OPV regimen. The authors concluded that OPV and eIPV are highly effective in stimulating protective levels of immunity against poliovirus.

Each regimen has advantages and disadvantages regarding ease of

TABLE 4. Polio Vaccination Schedule Options

DOSE	OPV ONLY	eIPV/OPV	eIPV ONLY
1	2 months	2 months (eIPV)	2 months
2	4 months	4 months (eIPV)	4 months
3	6 to 18 months	6 to 18 months (OPV)	6 to 18 months
4	4 to 6 years	4 to 6 years (OPV)	4 to 6 years

TABLE 5. Comparison of Polio Vaccination Regimens

REGIMEN	ADVANTAGES	DISADVANTAGES
All-OPV	<ul style="list-style-type: none"> • Induces intestinal immunity • Administration is easy • Provides herd immunity 	<ul style="list-style-type: none"> • Can cause VAPP • Requires refrigeration
eIPV/OPV	<ul style="list-style-type: none"> • Should reduce VAPP in healthy individuals • Delays OPV use in children who have undiagnosed immunodeficiencies • Maintains mucosal immunity • Maintains herd immunity 	<ul style="list-style-type: none"> • May not eliminate VAPP in contacts • Increased number of injections needed
All-eIPV	<ul style="list-style-type: none"> • Eliminates risk of VAPP 	<ul style="list-style-type: none"> • Minimal mucosal immunity • No herd immunity • Increased number of injections needed

Note: All three vaccination regimens are considered highly effective in preventing paralytic poliomyelitis.

administration, population immunity, and risk of VAPP (Table 5).

Conclusion

Because multiple nonpolio enteroviral serotypes are responsible for clinical illness, prevention by vaccination probably will not be possible in the near future. High-risk populations, such as those who have immunodeficiencies and neonates, would benefit greatly from effective treatments because infection among these children carries significant morbidity and mortality. Current efforts are focused on development

of novel antiviral compounds to treat enteroviral infections.

SUGGESTED READING

Abzug MJ, Keyserling HL, Lee ML, Levin MJ, Rothbart HA. Neonatal enterovirus infection: virology, serology, and effects of intravenous immune globulin. *Clin Infect Dis*. 1995;20:1201–1206

Abzug MJ, Levin MJ, Rothbart HA. Profile of enterovirus disease in the first two weeks of life. *Pediatr Infect Dis J*. 1993; 12:820–824

Cherry JD. Enteroviruses: polioviruses (poliomyelitis), coxsackieviruses, echoviruses and enteroviruses. *Textbook of Pediatric Infectious Diseases*. 3rd ed. Philadelphia, Penn: WB Saunders Co; 1992:1705–1753

Faden H. Poliovirus vaccination: a trilogy. *J Infect Dis*. 1993;168:25–28

Modlin JF. Update on enterovirus infections in infants and children. *Adv Pediatr Infect Dis*. 1997;12:155–179

Plotkin SA. Inactivated polio vaccine for the United States: a missed vaccination opportunity. *Pediatr Infect Dis J*. 1995; 14:835–839

1997 Red Book: Report of the Committee on Infectious Diseases. 24th ed. Elk Grove Village, Ill: American Academy of Pediatrics; 1997

Rothbart HA. Enteroviral infections of the central nervous system. *Clin Infect Dis*. 1995;20:971–981

Wilfert CM, Nusinoff Lehrman S, Katz SL. Enteroviruses and meningitis. *Pediatr Infect Dis*. 1983;2:333–341

PIR QUIZ

1. A febrile illness associated with severe headache and an acral rash assumes epidemic proportions in your New England town during August. The feature *most* atypical for an enteroviral origin would be:
 - A. Aseptic meningitis.
 - B. Biphasic course.
 - C. Herpangina.
 - D. Mid-summer occurrence.
 - E. Sparing of infants.
2. The *most* important benefit derived from replacing oral polio vaccine with enhanced potency inactivated poliovirus vaccine is:
 - A. Elimination of vaccine-associated paralytic poliomyelitis.
 - B. Greater ease of administration.
 - C. Greater overall effectiveness.
 - D. Higher levels of intestinal secretory IgA.
 - E. Strengthened herd immunity.
3. A previously healthy 6-day-old girl suddenly becomes febrile and lethargic. Vaginal delivery of this term infant was uneventful, and the nursery stay was unremarkable. The mother had been in excellent health throughout the pregnancy until early July when, 3 days before delivery, she developed a moderate headache, photophobia, and low-grade fever that resisted diagnosis. All symptoms resolved 12 hours after delivery. While appropriately entertaining and exploring the possibility of bacterial sepsis in the infant, you suspect enteroviral infection, given the clinical setting. The *most* sensitive diagnostic test for enterovirus in this circumstance is:
 - A. Blood culture.
 - B. Cerebrospinal fluid (CSF) cell count.
 - C. CSF cell culture.
 - D. CSF polymerase chain reaction.
 - E. Virus-specific serum IgM.
4. A previously healthy 4-year-old boy presents with a 2-day history of sore throat and fever. The findings on physical examination that predict an enteroviral explanation with highest confidence are:
 - A. Bilateral tonsillar enlargement, diffuse erythematous rash.
 - B. Bilateral tonsillar exudate, soft palate petechiae.
 - C. Friable gingiva, multiple ulcers of gums and tongue.
 - D. Hoarse voice, mild stridor.
 - E. Ulceration on anterior tonsillar pillars and adjoining soft palate.
5. Three days after recovering uneventfully from a transient fever and mild irritability, a 2-year-old boy begins to complain of a severe headache, and fever recurs. He previously has been well and is appropriately immunized. On examination, abnormal findings include a rectal temperature of 39°C (102.2°F), irritability, nuchal rigidity, and a diffuse maculopapular rash. Cerebrospinal fluid findings *most* consistent with an enteroviral meningitis are:
 - A. 20 cells/mm³, 70% granulocytes, glucose 0, protein 100.
 - B. 200 cells/mm³, 100% lymphocytes, glucose 20, protein 250.
 - C. 200 cells/mm³, 70% granulocytes, glucose 65, protein 45.
 - D. 3,500 cells/mm³, 70% granulocytes, glucose 20, protein 150.
 - E. 3,500 cells/mm³, 70% lymphocytes, glucose 40, protein 100.

Enterovirus Infections
Theoklis Zaoutis and Joel D. Klein
Pediatrics in Review 1998;19;183
DOI: 10.1542/pir.19-6-183

Updated Information & Services	including high resolution figures, can be found at: http://pedsinreview.aappublications.org/content/19/6/183
References	This article cites 7 articles, 3 of which you can access for free at: http://pedsinreview.aappublications.org/content/19/6/183#BIBL
Subspecialty Collections	This article, along with others on similar topics, appears in the following collection(s): Infectious Diseases http://pedsinreview.aappublications.org/cgi/collection/infectious_diseases
Permissions & Licensing	Information about reproducing this article in parts (figures, tables) or in its entirety can be found online at: /site/misc/Permissions.xhtml
Reprints	Information about ordering reprints can be found online: /site/misc/reprints.xhtml

American Academy of Pediatrics
DEDICATED TO THE HEALTH OF ALL CHILDREN™

