

CLINICAL PRACTICE

Precocious Puberty

Jean-Claude Carel, M.D., and Juliane Léger, M.D.

This Journal feature begins with a case vignette highlighting a common clinical problem. Evidence supporting various strategies is then presented, followed by a review of formal guidelines, when they exist. The article ends with the authors' clinical recommendations.

The parents of a 6-year-old girl bring her to a pediatrician because of breast development. Her medical history is unremarkable. The parents are of average height, and the mother reports first menstruating when she was 11 years old. At physical examination, the girl is 125 cm tall (in the 97th percentile for her age), weighs 28 kg, and has a body-mass index (the weight in kilograms divided by the square of the height in meters) of 17.9 (90th percentile for her age). Her pubertal development is classified as Tanner stage 3 breast development and Tanner stage 2 pubic hair development. A review of her previous growth data indicates that she has grown 8 cm during the past year. How should her condition be evaluated and managed?

THE CLINICAL PROBLEM

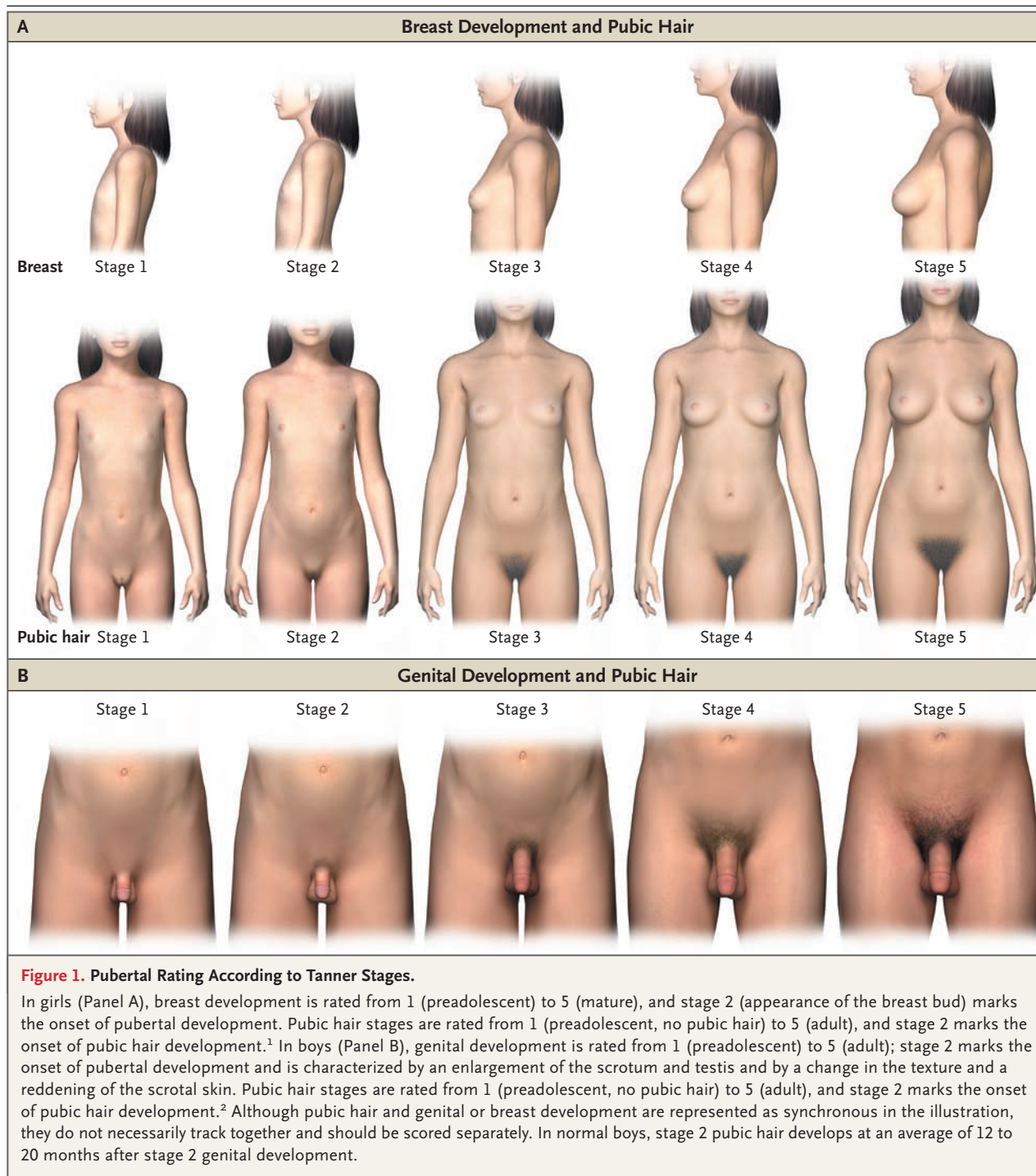
From the Department of Pediatric Endocrinology and Diabetology, INSERM Unité 690, and Centre de Référence des Maladies Endocriniennes de la Croissance, Robert Debré Hospital and University of Paris 7 — Denis Diderot, Paris (J.-C.C., J.-L.). Address reprint requests to Dr. Carel at Endocrinologie Diabétologie Pédiatrique and INSERM U690, Hôpital Robert Debré, 48, Blvd. Sérurier, 75935 Paris CEDEX 19, France, or at jean-claude.carel@inserm.fr.

N Engl J Med 2008;358:2366-77.
Copyright © 2008 Massachusetts Medical Society.

Puberty results when pulsatile secretion of gonadotropin-releasing hormone (GnRH) is initiated and the hypothalamo–pituitary–gonadal axis is activated. Tanner stages (Fig. 1) are used to evaluate pubertal development. The onset of puberty is marked by breast development in girls (Tanner stage 2 breast development, best assessed by both inspection and palpation) and testicular enlargement in boys (Tanner stage 2 genital development, assessed as testicular volume greater than 4 ml or testicular length greater than 25 mm).^{1,2} Physicians evaluating patients with suspected precocious puberty should address several questions: Is pubertal development really occurring outside the normal temporal range? What is the underlying mechanism, and is it associated with a risk of a serious condition, such as an intracranial lesion? Is pubertal development likely to progress, and if so, would this impair the child's normal physical and psychosocial development?

Cross-sectional data obtained in the 1960s led to designation of the normal age range of pubertal onset (the age at which 95% of children attain Tanner stage 2) as between 8 and 13 years in girls and between 9 years 6 months and 13 years 6 months in boys.^{1,2} More recently, cross-sectional data obtained in the United States indicated that pubertal milestones were being reached earlier than previously thought by black girls and to a lesser extent by Mexican-American and white girls.³⁻⁶ These observations led to recommendations to classify pubertal development as precocious when it occurs before the ages of 6 years in black girls and 7 years in all other girls.⁷ However, the validity of these recommendations has been questioned, and most pediatric endocrinologists in the United States use the traditional threshold of 8 years to define precocious pubertal development in girls.⁸ Although a similar tendency toward earlier puberty was also noted in Europe, the shift was less marked, and there, the lower end of the normal range for the onset of puberty is also 8 years in girls and 9 years 6 months in boys.⁹

The onset of puberty is affected by many factors in addition to race¹⁰; it occurs earlier in girls with early maternal menarche, low birth weight, or excessive weight



gain or obesity in infancy and early childhood, after international adoption (for unclear reasons, the risk is 10 to 20 times as great for these children¹¹), and possibly after exposure to estrogenic endocrine-disrupting chemicals or when no father is present in the household.^{10,12} However,

these factors account for only a fraction of the variation in the timing of pubertal onset and are not considered in definitions of normality in practice. It is important to recognize that a “normal” timing of the onset of pubertal development does not rule out a pathologic condition.^{13,14}

The prevalence of precocious puberty is about 10 times as high in girls as in boys, with an estimated prevalence of 0.2% among girls and less than 0.05% among boys in Denmark.¹⁵

The most common mechanism of progressive precocious puberty is the early activation of pulsatile gonadotropin-releasing hormone (GnRH) secretion (central or gonadotropin-dependent precocious puberty), which may result from hypothalamic tumors or lesions but in most cases remains unexplained (Table 1).¹⁶ Several causes of peripheral or gonadotropin-independent puberty are recognized, including gonadal and adrenal tumors and tumors producing human chorionic gonadotropin, activation of mutations in the gonadotropic pathway, and exposure to exogenous sex steroids (Table 1). Peripheral precocious puberty can lead to activation of pulsatile GnRH secretion and to central precocious puberty.

In at least 50% of cases of precocious pubertal development, pubertal manifestations will regress or stop progressing, and no treatment is necessary.¹⁷ Although the mechanism underlying these cases of nonprogressive precocious puberty is unknown, the gonadotropic axis is not activated. For cases in which precocious puberty progresses, concerns include early menarche in girls and short adult stature due to early epiphyseal fusion and adverse psychosocial outcomes in both sexes.¹⁸ Parents often seek treatment in girls because they fear early menarche,¹⁹ but it is difficult to predict the age at which menarche will occur after the onset of puberty. In the general population, the time from breast development to menarche is longer for children with an earlier onset of puberty, ranging from a mean of 2.8 years when breast development begins at the age of 9 years to 1.4 years when breast development begins at the age of 12.²⁰

Several studies have assessed adult height in people with a history of precocious puberty. In older published series of untreated patients, mean heights ranged from 151 to 156 cm in boys and from 150 to 154 cm in girls, corresponding to a loss of about 20 cm in boys and 12 cm in girls as compared with normal adult height.²¹ Height loss due to precocious puberty is inversely correlated with the age at the onset of puberty, and today, treated patients tend to have a later onset of puberty than did patients in historical series.²¹ Adverse psychosocial outcomes are also a concern, but the available data that are specific to patients with precocious puberty have serious

limitations.²² Data from surveys of the general population have indicated that a higher proportion of early-maturing adolescents engage in exploratory behaviors (sexual intercourse and legal and illegal substance use), and at an earlier age, than adolescents maturing within the normal age range or later.^{23,24} However, the relevance of these findings to precocious puberty is unclear, and they should not be used to justify intervention.

STRATEGIES AND EVIDENCE

EVALUATION

The first step in evaluating a child with precocious puberty is to obtain a complete family history (age at onset of puberty in parents and siblings) and personal history, including the age at onset of puberty and progression of pubertal manifestations, and any evidence suggesting possible central nervous system dysfunction, such as headache, increased head circumference, visual impairment, or seizures. Growth should be evaluated, because progressive precocious puberty is almost invariably associated with a high growth velocity; a high growth velocity may also precede the onset of pubertal manifestations.²⁵

The stage of pubertal development should be classified as described by Tanner. Careful assessment is needed in obese girls to avoid overestimating breast development (Fig. 1). The development of pubic hair results from the effects of androgens, which may be produced by testes or ovaries in central precocious puberty. In girls, pubic hair in the absence of breast development is suggestive of adrenal disorders, premature pubarche, or exposure to androgens (Table 1). In boys, measurement of testicular volume may suggest the cause of puberty; volume increases in central precocious puberty as it does in normal puberty (Fig. 1) and in cases of peripheral precocious puberty due to testicular disorders (although generally less so); volume remains prepubertal in adrenal disorders, premature pubarche, and other causes of peripheral precocious puberty. The physical examination should include an assessment for signs of specific causes of precocious puberty, such as hyperpigmented skin lesions suggesting neurofibromatosis or the McCune–Albright syndrome (Table 1). Precocious pubertal changes have been associated with high levels of anxiety in girls,^{19,23} and psychological evaluation may be useful.

ADDITIONAL TESTING

Although no evidence-based algorithm is available to guide testing, evaluation of the mechanism and potential for progression of precocious puberty is generally recommended in all boys with precocious pubertal development and in girls who have precocious breast development at stage 3 or higher or at stage 2 with additional criteria such as increased growth velocity or who have symptoms or signs suggestive of central nervous system dysfunction or of peripheral precocious puberty. Table 2 summarizes the features identified in cross-sectional and small longitudinal studies as potentially useful in distinguishing between progressive and nonprogressive precocious puberty. Particularly when these features are inconsistent, the best policy is to wait a few months and perform a reassessment in order to avoid unnecessary treatment.²⁸

Bone Age

A reference atlas such as the one by Greulich and Pyle can be used to evaluate the effect of sex steroids on epiphyseal maturation; the bone age of patients with precocious puberty is generally greater than their chronologic age. Bone age can also be used to predict adult height, although the precision is low (with a 95% confidence interval of about 6 cm below to 6 cm above the predicted value), and predictions tend to overestimate adult height.²⁹

Hormonal Measurements

Levels of sex steroids should be determined in the morning, with the use of assays that have detection limits adapted to pediatric values (Table 3). Most boys with precocious puberty have morning plasma testosterone values in the pubertal range.³⁰ In girls, serum estradiol levels are highly variable and have a low sensitivity for the diagnosis of precocious puberty. Very high estradiol levels (above 100 pg per milliliter [367 pmol per liter]) generally indicate an ovarian cyst or tumor (Table 1). Gonadotropin determinations (based on ultrasensitive assays) are central to the diagnosis. The gold standard for evaluation is the measurement of gonadotropins after stimulation by GnRH (which is unavailable in the United States) or a GnRH-releasing hormone agonist. Peak luteinizing hormone levels of 5 to 8 IU per liter suggest progressive central precocious puberty, but there is an overlap between prepubertal and early pubertal values.³¹ Random measure-

ments of luteinizing hormone have been proposed as an alternative; in one study, randomly measured values of 0.3 IU per liter and above were reported to be 100% specific for peak values above 5 IU per liter.³² However, unless levels of luteinizing hormone are clearly elevated, it is advisable to confirm the diagnosis of progressive central precocious puberty with a stimulation test before initiating treatment. Caution should be used when interpreting gonadotropin levels in children younger than 2 or 3 years old, because gonadotropin levels are normally high in this age group. Random measurements of follicle-stimulating hormone are not useful, since they vary little throughout pubertal development.

Pelvic or Testicular Ultrasound Scans

In girls, pelvic ultrasonography can reveal ovarian cysts or tumors. Uterine changes due to estrogen exposure can be used as an index of progressive puberty, but this approach is used much less frequently in the United States than in Europe. A uterine volume greater than 2.0 ml has been reported to have 89% sensitivity and specificity for precocious puberty.²⁶ Testicular ultrasonography can detect nonpalpable Leydig-cell tumors and should be performed in cases of asymmetric testicular volume or peripheral precocious puberty.³³

Brain Magnetic Resonance Imaging

In all cases of progressive central precocious puberty, magnetic resonance imaging (MRI) of the brain should be performed to determine whether a hypothalamic lesion is present (Table 1).³⁴ The prevalence of such lesions is higher in boys (40 to 90%) than in girls (8 to 33%) presenting with precocious puberty and is much lower when puberty starts after the age of 6 years in girls (about 2% in one series).^{14,35} It has been suggested that an algorithm based on age and estradiol levels may obviate the need for MRI in one third of girls, but this practice has not been extensively validated.^{14,34}

MANAGEMENT

CENTRAL PRECOCIOUS PUBERTY

GnRH agonists are indicated in progressive central precocious puberty. They work by providing continuous stimulation of the pituitary gonadotrophs, leading to desensitization and decreases in the release of luteinizing hormone and, to a

Table 1. The Causes of Precocious Puberty.*

Disorder	Characteristic Symptoms and Signs	Test Results
Progressive central or gonadotropin-dependent precocious puberty		
Overview	Breast development or testicular enlargement with or without pubic hair development; increased growth velocity; possible acne, oily skin and hair, and emotional changes	High serum testosterone in boys, variable serum estradiol in girls; peak serum LH level after GnRH stimulation in the pubertal range; advanced bone age; developed uterus on ultrasound examination
No CNS lesion	Possible history of familial precocious puberty or adoption; no CNS lesion in approximately 92% of girls and approximately 50% of boys; can also be part of a developmental syndrome such as Williams–Beuren syndrome or maternal uniparental disomy of chromosome 14	No hypothalamic abnormality found on MRI of brain; possible enlargement of pituitary
CNS lesion		
Hypothalamic hamartoma	Possible association of lesion with gelastic (laughing), focal, or tonic–clonic seizures	Mass in floor of third ventricle found on MRI, isointense in relation to normal tissue without contrast enhancement
Other hypothalamic tumor (e.g., glioma involving the hypothalamus or optic chiasm, astrocytoma, ependymoma, pinealoma, or germ-cell tumor)	Possible headache, visual changes, cognitive changes, symptoms or signs of anterior or posterior pituitary deficiency (e.g., decreased growth velocity, polyuria or polydipsia), fatigue, and visual-field defects; if CNS tumor is associated with neurofibromatosis, other features of neurofibromatosis (e.g., cutaneous neurofibromas, café au lait spots, Lisch nodules)	Possible contrast-enhanced mass found on MRI involving optic pathways (chiasm, nerve, tract) or hypothalamus alone (in the case of astrocytoma or glioma) or hypothalamus and pituitary stalk (in the case of a germ-cell tumor); possible evidence of intracranial hypertension; possible signs of anterior or posterior pituitary deficiency (e.g., hypernatremia); with germ-cell tumor, can detect β -hCG in blood or CSF
Cerebral malformations involving the hypothalamus — suprasellar arachnoid cyst, hydrocephalus, septo-optic dysplasia, myelomeningocele, ectopic neurohypophysis	Possible neurodevelopmental deficits, macrocrania, visual impairment, nystagmus, obesity, polyuria or polydipsia, or decreased growth velocity	Possible signs of anterior or posterior pituitary deficiency (e.g., hypernatremia) or hyperprolactinemia
Injury — cranial irradiation, head trauma, infection, perinatal insult	Relevant history of injury; possible symptoms and signs of anterior or posterior pituitary deficiency	Possible finding on MRI of condition-specific sequelae — or may be normal
Early exposure to sex steroids (after cure of gonadotropin-independent precocious puberty)	History of such exposure	
Peripheral or gonadotropin-independent precocious puberty		
Overview	Varied pubertal symptoms depending on nature of sex steroid produced; typically, smaller testicular volume than in central precocious puberty	High serum testosterone in boys, generally high and occasionally markedly elevated serum estradiol in girls; low (suppressed) peak serum LH after GnRH stimulation; advanced bone age; developed uterus on ultrasound examination
Autonomous gonadal activation		
McCune–Albright syndrome and recurrent autonomous ovarian cysts due to somatic activating mutation of the GNAS gene resulting in increased signal transduction in the Gs pathway	Found mostly in girls; typically rapid progression of breast development and early occurrence of vaginal bleeding (before or within a few months after the start of breast development); precocious puberty isolated or associated with café au lait skin lesions or bone pain due to polyostotic fibrous dysplasia; in rare cases other signs of endocrine hyperfunction (e.g., hypercortisolism, hyperthyroidism), liver cholestasis, or cardiac rhythm abnormalities	Typically large ovarian cyst or cysts on pelvic ultrasound examination; bone lesions of fibrous dysplasia; possible laboratory evidence of hypercortisolism, hyperthyroidism, increased GH secretion, hypophosphatemia, or liver cholestasis
Germ-line mutation of GNAS gene resulting in dual loss and gain of function (rare)	Features of gonadotropin-independent precocious puberty and pseudohypoparathyroidism type 1a in boys	Temperature-sensitive point mutation in the GNAS gene resulting in activation at testis temperature and loss of function at body temperature

<p>Familial male-limited precocious puberty due to germinal activating mutations of the LH receptor gene</p>	<p>Possible familial history of dominant precocious puberty in boys (can be transmitted by mothers), with some sporadic cases</p>	<p>Activating mutation of LH receptor gene.</p>
<p>Tumors</p>		
<p>Granulosa-cell tumor of the ovary</p>	<p>Rapid progression of breast development and possible abdominal pain; tumor may be palpable on abdominal examination</p>	<p>Tumor detection on ultrasound or CT scan</p>
<p>Androgen-producing ovarian tumor</p>	<p>Progressive virilization</p>	<p>Tumor detection on ultrasound or CT scan</p>
<p>Testicular Leydig-cell tumor</p>	<p>Progressive virilization; testicular asymmetry; tumor palpable in rare cases</p>	<p>Tumor detection on testicular ultrasound</p>
<p>hCG-producing tumor</p>	<p>Tumors can originate in the liver or mediastinum; pubertal symptoms in boys only; may be associated with Klinefelter's syndrome</p>	<p>Elevated serum hCG; tumor detection on ultrasound or CT scan</p>
<p>Adrenal disorders</p>		
<p>Congenital adrenal hyperplasia</p>	<p>Increased androgen production, leading to virilization in boys and girls</p>	<p>Increased adrenal steroid precursors in serum, mainly 17-hydroxyprogesterone (basal or after a corticotropin stimulation test)</p>
<p>Adrenal tumor</p>	<p>Increased androgen production, leading to virilization in boys and girls; in rare cases estrogen-producing adrenal tumor</p>	<p>Tumor on abdominal ultrasound or CT scan; elevated DHEAS or adrenal steroid precursors</p>
<p>Condition due to exposure to exogenous agents</p>		
<p>Sex steroids</p>		
<p>Estrogenic endocrine-disrupting chemicals</p>	<p>Varied manifestations depending on type of preparation (androgenic or estrogenic); most commonly described after topical exposure to androgens; possible difficulty tracing source of exposure</p>	<p>Misleading endocrine evaluation possible due to variable serum levels of sex steroids</p>
<p>Severe, untreated primary hypothyroidism</p>		
<p>Estrogenic endocrine-disrupting chemicals</p>	<p>Although unproven, possible role of exposure in precocious puberty among adopted children (by modulating timing of activation of pubertal gonadotropic axis)</p>	<p>No validated biochemical test</p>
<p>Severe, untreated primary hypothyroidism</p>	<p>Signs of hypothyroidism; no increase in growth velocity</p>	<p>Elevated serum levels of thyrotropin, low levels of free thyroxine; no advancement in bone age</p>
<p>Benign variants of precocious pubertal development</p>		
<p>Overview</p>		
<p>Nonprogressive precocious puberty</p>	<p>Stabilization or regression of pubertal signs; normal growth velocity; follow-up is warranted since progression can occur</p>	<p>Bone age within two standard deviations of normal for age; low serum levels of sex steroids; peak serum LH levels after GnRH stimulation in prepubertal range; normal pelvic ultrasound examination</p>
<p>Isolated precocious thelarche</p>	<p>Unilateral or bilateral breast development; particularly frequent before the age of 2 yr</p>	<p>No further evaluation needed in most cases</p>
<p>Isolated precocious pubarche</p>	<p>Pubic hair development, sometimes associated with adult body odor, axillary hair, or mild acne</p>	<p>Normal cortisol precursors in serum, including normal levels of 17-hydroxy progesterone after corticotropin stimulation</p>
<p>Isolated precocious menarche</p>	<p>Isolated vaginal bleeding without breast or pubic-hair development and without genital trauma; important to evaluate clinically for a vaginal lesion (sexual abuse, foreign body, tumor)</p>	<p>Normal bone age and prepubertal uterus on ultrasound examination</p>

* CNS denotes central nervous system, CSF cerebrospinal fluid, CT computed tomography, DHEAS dehydroepiandrosterone sulfate, GH growth hormone, GNAS guanine nucleotide-binding protein alpha subunit, GnRH gonadotropin-releasing hormone, Gs stimulatory guanine nucleotide-binding protein, hCG human chorionic gonadotropin, LH luteinizing hormone, and MRI magnetic resonance imaging.

Table 2. Criteria for Differentiating Progressive from Nonprogressive Forms of Precocious Puberty in Girls.*

Criterion	Progressive Central Precocious Puberty	Nonprogressive Precocious Puberty
Clinical		
Progression through pubertal stages	Progression from one stage to the next in 3–6 mo	Stabilization or regression of pubertal signs
Growth velocity	Accelerated (> about 6 cm per yr)	Usually normal for age
Bone age	Usually advanced by at least 1 yr	Usually within 1 yr of chronologic age
Predicted adult height	Below target height range or declining on serial determinations	Within target height range
Uterine development†‡		
Pelvic ultrasound scan	Uterine volume >2.0 ml or length >34 mm, pear-shaped uterus, endometrial thickening (endometrial echo)	Uterine volume ≤2.0 ml or length ≤34 mm; prepubertal, tubular-shaped uterus
Hormone levels		
Estradiol	Usually measurable estradiol level with advancing pubertal development	Estradiol not detectable or close to the detection limit
LH peak after GnRH or GnRH agonist‡	In the pubertal range	In the prepubertal range

* These criteria were developed to distinguish progressive central precocious puberty (characterized by a sustained activation of the gonadotropic axis) from nonprogressive precocious puberty (in which the gonadotropic axis is not activated) and were obtained in cross-sectional and small longitudinal studies; their reliability has not been fully evaluated.^{18,26,27} GnRH denotes gonadotropin-releasing hormone, and LH luteinizing hormone.

† Pelvic ultrasonography is used much more frequently in Europe than in the United States. Uterine development reflects sustained exposure to estrogens and is a marker of progressive puberty.

‡ GnRH is not available in the United States for use in testing.

lesser extent, follicle-stimulating hormone.³⁶ Several GnRH agonists are available in depot forms (Table 4). In open-label, noncomparative, longitudinal studies, the use of GnRH agonists consistently resulted in the regression or stabilization of pubertal symptoms.^{41,42} A suppressed luteinizing hormone response to GnRH or a GnRH agonist or a suppressed response after an injection of the depot preparation (which contains a fraction of free GnRH agonist) indicates that the therapy is having the desired effect.⁴³

There are no data from randomized controlled trials assessing long-term outcomes of GnRH therapy for central precocious puberty. Among approximately 400 girls who received such treatment until the age of 11 years on average, the mean adult height was about 160 cm; mean gains over predicted height in several series of patients ranged from 3 to 10 cm.²¹ Individual height gains varied considerably but were calculated on the basis of predicted height, which is unreliable. Factors affecting height gains include baseline bone age (with markedly advanced bone age associated with shorter adult height) and, in some series, duration of treatment (with a younger age at the

start of treatment and a longer duration of treatment associated with greater height^{44,45}). The optimal time to stop treatment has not been established, but retrospective analyses suggest that discontinuation at the age of 11 years is associated with optimal height outcomes (i.e., no appreciable further gains with continued treatment).⁴⁶ Pubertal manifestations generally reappear within months after GnRH-agonist treatment has been stopped, with a mean time to menarche of 16 months.⁴⁷ Long-term fertility has not been fully evaluated, but preliminary observations are reassuring.⁴⁷

Treatment may be associated with headaches and menopausal symptoms (e.g., hot flashes). Local complications, including sterile abscesses at injection sites, occur in 3 to 13% of patients.⁴⁸ Fat mass tends to increase with treatment, whereas lean mass and bone density tend to decrease. Concerns have been raised about possible risks of obesity and osteoporosis,^{49,50} but longitudinal studies indicate that the prevalence of obesity does not increase during or after treatment and that bone density is normal after the cessation of treatment.^{50,51}

Table 3. Hormonal Evaluation for Precocious Puberty.*

Variable	Technical Requirements	Significance	Limitations	Recommendations for Use
Serum estradiol (girls)	Use morning values and an assay with a lower limit of detection of approximately 5 pg/ml (18 pmol/liter) or lower	Elevated levels are indicative of estrogen production or exposure; markedly elevated levels (> about 100 pg/ml [367 pmol/liter]) suggest an ovarian cyst or a tumor	Levels can be normal in progressive central precocious puberty; there are difficulties in interpreting values measured with immunoenzymatic methods	Use as a first-line test with basal LH in girls, but note poor sensitivity in discriminating between early pubertal and prepubertal levels
Serum testosterone	Use morning values and an assay with a lower limit of detection of approximately 10 ng/dl (0.35 nmol/liter)	Elevated levels are a reliable marker of testicular activation in boys; in girls, elevated testosterone levels suggest an adrenal disorder	There are difficulties in interpreting values measured with immunoenzymatic methods	Use as a first-line test with basal LH in boys — high sensitivity for confirming precocious puberty; for girls, measure only if there are signs of hyperandrogenism
Serum LH	Use morning values and ultrasensitive assays with a detection limit of approximately 0.1 IU/liter or lower	Basal LH measurements poorly discriminate between prepubertal and early pubertal children; values >0.3–0.4 IU/liter are indicative of central precocious puberty, with a high specificity and a low sensitivity	There are wide interassay variations; assay characteristics must be taken into account in interpreting the results	Use as a first-line screening test in association with estradiol or testosterone measurement; clearly elevated levels can obviate the need for a stimulation test
Peak LH after stimulation with GnRH or GnRH agonist†	Level can be checked at any time of the day; assay requirements similar to those for baseline measurements	Peak LH level above the pubertal cutoff with elevated sex steroid levels indicate progressive central puberty; suppressed peak LH level with elevated sex steroid levels indicate peripheral precocious puberty	LH levels vary according to the assay used; paucity of normative values to define cutoffs; values of 5 to 8 IU/liter often considered high in children 3 to 8 yr old; higher cutoffs should be used in children younger than 2 yr old because of transient activation of gonadotropic axis; peak values vary with the stimulating agent used (GnRH or GnRH agonist)	Use to diagnose central precocious puberty
Peak FSH after stimulation with GnRH or GnRH agonist†		Peak LH:FSH ratio typically increases during puberty; high ratios have been used as a criterion for progressive central puberty; not in common use now that more sensitive LH assays are available	This measure is poorly validated, in particular with sandwich antibody assays for gonadotropin measurements	Use as an additional criterion when a GnRH or GnRH-agonist test is performed
Serum β -hCG		Produced by germ-cell tumors; detection in serum is indicative of peripheral or intracranial tumors, in CSF indicative of intracranial tumors	Peripheral production of β -hCG leads to pubertal development only in boys	Measure serum level in boys with peripheral precocious puberty to identify a germ-cell tumor; measure in the CSF when a lesion compatible with a germ-cell tumor is detected on MRI
Serum DHEAS		Produced by adrenals; detection is a marker of androgen-producing adrenal tumors or of adrenal enzymatic defect	Level is also increased in precocious pubarche	Measure if androgenic signs (pubic hair) predominate
Serum 17-hydroxyprogesterone	Use morning values or measure after corticotropin stimulation	Elevated levels are a marker of adrenal enzymatic defects (congenital adrenal hyperplasia); levels are occasionally elevated with adrenal tumors	Borderline elevations are frequent in unaffected carriers of nonclassic congenital adrenal hyperplasia	Measure if androgenic signs (pubic hair) predominate

* CSF denotes cerebrospinal fluid, DHEAS dehydroepiandrosterone sulfate, FSH follicle-stimulating hormone, GnRH gonadotropin-releasing hormone, hCG human chorionic gonadotropin, and LH luteinizing hormone. Morning values are recommended when testing levels of sex steroids and LH because of circadian rhythms.

† GnRH is not available in the United States for use in testing.

Table 4. Medications Used for the Treatment of Precocious Puberty.*

Drug	Formulation and Usually Recommended Dose	Side Effects and Cautions
For treatment of central or gonadotropin-dependent precocious puberty		
Depot GnRH agonists†		
Overview		Local side effects include pain, erythema, inflammatory reaction, sterile abscess, implant-site reaction; other side effects include headaches and menopausal-like symptoms (hot flushes, asthenia); decreased bone density during treatment but no long-term impairment documented after treatment is discontinued
Leuporelin leuprolide (Enantone [Takeda], Lupron Depot [TAP], Lupron Depot-PED [TAP]‡)	4-wk and 12-wk preparations (subcutaneous or intramuscular); United States — 0.3 mg/kg of body weight every 4 wk (1-mo depot); Europe — 3.75 mg every 4 wk (4-wk depot) or 11.25 mg every 12 wk (12-wk depot)	
Triptorelin (Decapeptyl [Ipsen, Ferring], Gonapeptyl [Ferring])§	4-wk and 12-wk preparations (intramuscular); Europe — 3.00–3.75 mg every 4 wk (1-mo depot) or 11.25 mg every 12 wk (3-mo depot)	
Goserelin (Zoladex [AstraZeneca], 3.6 mg or 10.8 mg)	4-wk and 12-wk implants	
Histrelin (Supprelin LA [Indevus]‡)	12-mo implants United States — 50-mg implant every 12 mo	
Rapid-acting GnRH agonists — busarelin, deslorelin, histrelin, leuporelin, leuprolide, nafarelin, triptorelin	Nasal spray or subcutaneous injections 1–3 times daily	Difficulties with compliance; use usually limited to patients with sterile abscesses from depot injections
For treatment of peripheral or gonadotropin-independent precocious puberty¶		
Aromatase inhibitors		
Testolactone (Teslac [Bristol-Myers Squibb])	40 mg/kg of body weight/day orally, 4–6 times daily	Data from small, uncontrolled trials in McCune–Albright syndrome; also used in association with spironolactone for familial male-limited precocious puberty ³⁷
Letrozole (Femara [Novartis])	2.5 mg orally once daily	Menopause-like symptoms; data from small, uncontrolled trial in McCune–Albright syndrome ³⁸
Anastrozole (Arimidex [AstraZeneca])	1 mg orally once daily	Data from case reports
SERM — Tamoxifen (Nolvadex [AstraZeneca])	20 mg orally once daily	Data from small, uncontrolled trials in McCune–Albright syndrome ³⁹
Androgen-synthesis inhibitor — ketoconazole (Nizoral [Janssen-Cilag])	20 mg/kg of body weight/day orally	Side effects include liver toxicity and adrenal deficiency; data from small, uncontrolled trials in familial male-limited precocious puberty ⁴⁰

* Drugs used for the treatment of adrenal disorders (congenital adrenal hyperplasia) are not included in this table. SERM denotes selective estrogen-receptor modulators.

† The availability, approval for use, and recommended dosages of depot GnRH agonists for the treatment of precocious puberty vary throughout the world.

‡ The Food and Drug Administration has approved Lupron Depot-PED and Supprelin LA for the treatment of central precocious puberty. Histrelin implants are available only in the United States.

§ Triptorelin is not available in the United States.

¶ None of these drugs have been approved for use in the treatment of precocious puberty.

For cases in which precocious puberty is caused by a central lesion (e.g., a mass or malformation), management of the causal lesion generally has no effect on the course of pubertal development. Hypothalamic hamartomas should not be removed surgically for the purpose of managing precocious puberty. When precocious puberty is associated with the presence of a hypothalamic lesion, there may be progression to gonadotropin deficiency.

PERIPHERAL PRECOCIOUS PUBERTY

Surgery is indicated for gonadal tumors. The roles of postoperative chemotherapy and radiotherapy in granulosa-cell tumors of the ovary at stage I or after complete resection have not been defined.⁵² For large ovarian cysts (those that are greater than 20 ml in volume [3.4 cm in diameter] and particularly those that are more than 75 ml in volume [5.2 cm in diameter]), puncture should be considered because of the risk of adnexal torsion.⁵³ If there is exposure to exogenous sex steroids, it should be withdrawn.

Aromatase inhibitors³⁸ have been used to inhibit the production of estrogens, and selective estrogen-receptor modulators³⁹ have been used to interfere with the action of estrogens in the McCune–Albright syndrome. Limited data from uncontrolled studies suggest that these strategies have been effective in some cases.

AREAS OF UNCERTAINTY

The appropriate age threshold for the definition of precocious puberty remains controversial; well-performed longitudinal assessments of normally developing children are needed to inform these criteria. The best approach for differentiating progressive from nonprogressive forms of precocious puberty remains unclear. The decision about whether to provide treatment is therefore often difficult, particularly for girls with an onset of puberty between the ages of 6 and 8 years. The most appropriate age for stopping treatment also remains uncertain. The addition of growth hormone⁵⁴ or oxandrolone⁵⁵ has been proposed when growth velocity decreases or if the prognosis for adult height appears to be unsatisfactory, but data are limited on the efficacy and safety of these

drugs in children with precocious puberty. Causal mechanisms underlying idiopathic precocious puberty also remain uncertain.¹⁶

GUIDELINES

A consensus statement on the use of GnRH agonists in children is currently being prepared by the European Society for Paediatric Endocrinology and its American counterpart, the Lawson Wilkins Pediatric Endocrine Society.

CONCLUSIONS AND RECOMMENDATIONS

In the case described in the vignette, advanced breast development (Tanner stage 3), pubic hair development, higher-than-expected height given parental height, and increased growth velocity at 6 years of age suggest progressive precocious puberty. Evidence of possible causes of precocious puberty should be sought by means of a thorough history taking and careful examination, but this search is often unrevealing. Further evaluation should include measurements of bone age (which would probably be advanced) and levels of estradiol and luteinizing hormone. If a randomly measured level of luteinizing hormone is in the pubertal range, an MRI scan of the brain should be obtained, and it would be useful to perform a GnRH-agonist stimulation test to confirm progressive central precocious puberty before considering treatment with a GnRH agonist. If the randomly measured level of luteinizing hormone is in the prepubertal range, a pelvic ultrasound scan is needed to rule out an ovarian tumor or cyst, particularly if the estradiol level is elevated. If randomly measured levels of both estradiol and luteinizing hormone are in the prepubertal range, we recommend performing a GnRH or GnRH-agonist stimulation test to further evaluate the activation of the gonadotropic axis and the potential for progression of puberty. If the results suggest nonprogressive precocious puberty, we recommend follow-up every 3 to 6 months between the ages of 6 and 7 years to assess the child clinically for progression. If progressive central precocious puberty is confirmed, treatment with a depot GnRH agonist is recom-

mended and is generally continued until the child is 11 years old, although the optimal duration of therapy is uncertain. [Educational information for families can be found at <http://eurospe.org/patient/English/index.html> or at www.hormone.org/Public/factsheets.cfm.]

Dr. Carel reports receiving grant funding from Ipsen and

Takeda; having been part of the organizing committee of a pediatric endocrinology consensus meeting supported in part by Indevus, Ipsen, Ferring, and TAP; and receiving lecture fees from Ferring. No other potential conflict of interest relevant to this article was reported.

We thank Drs. Jean-Louis Chaussain, Najiba Lahlou, and Marc Roger for their longstanding contributions to the field of precocious puberty.

An audio version of this article is available at www.nejm.org.

REFERENCES

1. Marshall WA, Tanner JM. Variations in the pattern of pubertal changes in boys. *Arch Dis Child* 1970;45:13-24.
2. *Idem*. Variations in the pattern of pubertal changes in girls. *Arch Dis Child* 1969;44:291-303.
3. Herman-Giddens ME, Slora EJ, Wasserman RC, et al. Secondary sexual characteristics and menses in young girls seen in office practice: a study from the Pediatric Research in Office Settings Network. *Pediatrics* 1997;99:505-12.
4. Herman-Giddens ME, Kaplowitz PB, Wasserman R. Navigating the recent articles on girls' puberty in *Pediatrics*: what do we know and where do we go from here? *Pediatrics* 2004;113:911-7.
5. Wu T, Mendola P, Buck GM. Ethnic differences in the presence of secondary sex characteristics and menarche among US girls: the Third National Health and Nutrition Examination Survey, 1988-1994. *Pediatrics* 2002;110:752-7.
6. Sun SS, Schubert CM, Chumlea WC, et al. National estimates of the timing of sexual maturation and racial differences among US children. *Pediatrics* 2002;110:911-9.
7. Kaplowitz PB, Oberfield SE. Reexamination of the age limit for defining when puberty is precocious in girls in the United States: implications for evaluation and treatment. *Pediatrics* 1999;104:936-41.
8. Rosenfield RL, Bachrach LK, Chernausk SD, et al. Current age of onset of puberty. *Pediatrics* 2000;106:622-3.
9. Mul D, Fredriks AM, van Buuren S, Oostdijk W, Verloove-Vanhorick SP, Wit JM. Pubertal development in the Netherlands 1965-1997. *Pediatr Res* 2001;50:479-86.
10. Parent AS, Teilmann G, Juul A, Skakkebaek NE, Toppari J, Bourguignon JP. The timing of normal puberty and the age limits of sexual precocity: variations around the world, secular trends, and changes after migration. *Endocr Rev* 2003;24:668-93.
11. Teilmann G, Pedersen CB, Skakkebaek NE, Jensen TK. Increased risk of precocious puberty in internationally adopted children in Denmark. *Pediatrics* 2006;118(2):e391-e399.
12. Matchock RL, Susman EJ. Family composition and menarcheal age: anti-inbreeding strategies. *Am J Hum Biol* 2006;18:481-91.
13. Midyett LK, Moore WV, Jacobson JD. Are pubertal changes in girls before age 8 benign? *Pediatrics* 2003;111:47-51.
14. Chalumeau M, Hadjiathanasiou CG, Ng SM, et al. Selecting girls with precocious puberty for brain imaging: validation of European evidence-based diagnosis rule. *J Pediatr* 2003;143:445-50.
15. Teilmann G, Pedersen CB, Jensen TK, Skakkebaek NE, Juul A. Prevalence and incidence of precocious pubertal development in Denmark: an epidemiologic study based on national registries. *Pediatrics* 2005;116:1323-8.
16. Nathan BM, Palmert MR. Regulation and disorders of pubertal timing. *Endocrinol Metab Clin North Am* 2005;34:617-41.
17. Kaplowitz P. Clinical characteristics of 104 children referred for evaluation of precocious puberty. *J Clin Endocrinol Metab* 2004;89:3644-50.
18. Klein KO. Precocious puberty: who has it? Who should be treated? *J Clin Endocrinol Metab* 1999;84:411-4.
19. Xhrouet-Heinrichs D, Lagrou K, Heinrichs C, et al. Longitudinal study of behavioral and affective patterns in girls with central precocious puberty during long-acting triptorelin therapy. *Acta Paediatr* 1997;86:808-15.
20. Marti-Henneberg C, Vizmanos B. The duration of puberty in girls is related to the timing of its onset. *J Pediatr* 1997;131:618-21.
21. Carel JC, Lahlou N, Roger M, Chaussain JL. Precocious puberty and statural growth. *Hum Reprod Update* 2004;10:135-47.
22. Dorn LD. Psychological and social problems in children with premature adrenarche and precocious puberty. In: Pescovitz OH, Walvoord EC, eds. *When puberty is precocious: scientific and clinical aspects*. Totowa, NJ: Humana Press, 2007:309-27.
23. Tremblay L, Frigon JY. Precocious puberty in adolescent girls: a biomarker of later psychosocial adjustment problems. *Child Psychiatry Hum Dev* 2005;36:73-94.
24. Michaud PA, Suris JC, Deppen A. Gender-related psychological and behavioural correlates of pubertal timing in a national sample of Swiss adolescents. *Mol Cell Endocrinol* 2006;254-255:172-8.
25. Papadimitriou A, Beri D, Tsiaila A, Fretzayas A, Psychou F, Nicolaidou P. Early growth acceleration in girls with idiopathic precocious puberty. *J Pediatr* 2006;149:43-6.
26. de Vries L, Horev G, Schwartz M, Phillip M. Ultrasonographic and clinical parameters for early differentiation between precocious puberty and premature thelarche. *Eur J Endocrinol* 2006;154:891-8.
27. Palmert MR, Malin HV, Boepple PA. Unsustained or slowly progressive puberty in young girls: initial presentation and long-term follow-up of 20 untreated patients. *J Clin Endocrinol Metab* 1999;84:415-23.
28. Léger J, Reynaud R, Czernichow P. Do all girls with apparent idiopathic precocious puberty require gonadotropin-releasing hormone agonist treatment? *J Pediatr* 2000;137:819-25.
29. Bar A, Linder B, Sobel EH, Saenger P, DiMartino-Nardi J. Bayley-Pinneau method of height prediction in girls with central precocious puberty: correlation with adult height. *J Pediatr* 1995;126:955-8.
30. Roger M, Lahlou N, Chaussain JL. Gonadotropin-releasing hormone testing in pediatrics. In: Ranke MB, ed. *Diagnostics of endocrine function in children and adolescents*. Heidelberg, Germany: Johann Ambrosius Barth Verlag, 1996:346-69.
31. Resende EA, Lara BH, Reis JD, Ferreira BP, Pereira GA, Borges ME. Assessment of basal and gonadotropin-releasing hormone-stimulated gonadotropins by immunochemiluminometric and immunofluorometric assays in normal children. *J Clin Endocrinol Metab* 2007;92:1424-9.
32. Neely EK, Wilson DM, Lee PA, Stene M, Hintz RL. Spontaneous serum gonadotropin concentrations in the evaluation of precocious puberty. *J Pediatr* 1995;127:47-52.
33. Liu G, Duranteau L, Carel J-C, Monroe J, Doyle DA, Shenker A. Leydig-cell tumors caused by an activating mutation of the gene encoding the luteinizing hormone receptor. *N Engl J Med* 1999;341:1731-6.
34. Stanhope R. Gonadotrophin-dependent precocious puberty and occult intracranial tumors: which girls should have neuro-imaging? *J Pediatr* 2003;143:426-7.
35. De Sanctis V, Corrias A, Rizzo V, et al. Etiology of central precocious puberty in males: the results of the Italian Study Group for Physiopathology of Puberty.

- J Pediatr Endocrinol Metab 2000;13: Suppl 1:687-93.
36. Lahlou N, Carel JC, Chaussain JL, Roger M. Pharmacokinetics and pharmacodynamics of GnRH agonists: clinical implications in pediatrics. J Pediatr Endocrinol Metab 2000;13:Suppl 1:723-37.
37. Leschek EW, Jones J, Barnes KM, Hill SC, Cutler GB Jr. Six-year results of spironolactone and testosterone treatment of familial male-limited precocious puberty with addition of deslorelin after central puberty onset. J Clin Endocrinol Metab 1999;84:175-8.
38. Feuilleux P, Calis K, Hill S, Shawker T, Robey PG, Collins MT. Letrozole treatment of precocious puberty in girls with the McCune-Albright syndrome: a pilot study. J Clin Endocrinol Metab 2007;92: 2100-6.
39. Eugster EA, Rubin SD, Reiter EO, Plourde P, Jou HC, Pescovitz OH. Tamoxifen treatment for precocious puberty in McCune-Albright syndrome: a multicenter trial. J Pediatr 2003;143:60-6.
40. Soriano-Guillén L, Lahlou N, Chauvet G, Roger M, Chaussain JL, Carel JC. Adult height after ketoconazole treatment in patients with familial male-limited precocious puberty. J Clin Endocrinol Metab 2005;90:147-51.
41. Neely EK, Hintz RL, Parker B, et al. Two-year results of treatment with depot leuprolide acetate for central precocious puberty. J Pediatr 1992;121:634-40.
42. Carel JC, Blumberg J, Seymour C, Adamsbaum C, Lahlou N. Three-month sustained-release triptorelin (11.25 mg) in the treatment of central precocious puberty. Eur J Endocrinol 2006;154:119-24.
43. Bhatia S, Neely EK, Wilson DM. Serum luteinizing hormone rises within minutes after depot leuprolide injection: implications for monitoring therapy. Pediatrics 2002;109(2):E30.
44. Klein KO, Barnes KM, Jones JV, Feuilleux PP, Cutler GB Jr. Increased final height in precocious puberty after long-term treatment with LHRH agonists: the National Institutes of Health experience. J Clin Endocrinol Metab 2001;86:4711-6.
45. Paul DL, Conte FA, Grumbach MM, Kaplan SL. Long-term effect of gonadotropin-releasing hormone agonist therapy on final and near-final height in 26 children with true precocious puberty treated at a median age of less than 5 years. J Clin Endocrinol Metab 1995;80:546-51.
46. Carel JC, Roger M, Ispas S, et al. Final height after long-term treatment with triptorelin slow release for central precocious puberty: importance of statural growth after interruption of treatment. J Clin Endocrinol Metab 1999;84:1973-8.
47. Heger S, Muller M, Ranke M, et al. Long-term GnRH agonist treatment for female central precocious puberty does not impair reproductive function. Mol Cell Endocrinol 2006;254-255:217-20.
48. Carel JC, Lahlou N, Jaramillo O, et al. Treatment of central precocious puberty by subcutaneous injections of leuprorelin 3-month depot (11.25 mg). J Clin Endocrinol Metab 2002;87:4111-6.
49. Boot AM, de Muinck Keizer-Schrama S, Pols HA, Krenning EP, Drop SL. Bone mineral density and body composition before and during treatment with gonadotropin-releasing hormone agonist in children with central precocious and early puberty. J Clin Endocrinol Metab 1998;83: 370-3.
50. Palmert MR, Mansfield MJ, Crowley WF Jr, Crigler JF Jr, Crawford JD, Boeppel PA. Is obesity an outcome of gonadotropin-releasing hormone agonist administration? Analysis of growth and body composition in 110 patients with central precocious puberty. J Clin Endocrinol Metab 1999;84:4480-8.
51. Bertelloni S, Baroncelli GI, Sorrentino MC, Perri G, Saggese G. Effect of central precocious puberty and gonadotropin-releasing hormone analogue treatment on peak bone mass and final height in females. Eur J Pediatr 1998;157:363-7.
52. Pectasides D, Pectasides E, Psyrri A. Granulosa cell tumor of the ovary. Cancer Treat Rev 2008;34:1-12.
53. Linam LE, Darolia R, Naffaa LN, et al. US findings of adnexal torsion in children and adolescents: size really does matter. Pediatr Radiol 2007;37:1013-9.
54. Pasquino AM, Pucarelli I, Segni M, Matrunola M, Cerroni F, Cerrone F. Adult height in girls with central precocious puberty treated with gonadotropin-releasing hormone analogues and growth hormone. J Clin Endocrinol Metab 1999;84:449-52. [Erratum, J Clin Endocrinol Metab 1999; 84:1978.]
55. Vottero A, Pedori S, Verna M, et al. Final height in girls with central idiopathic precocious puberty treated with gonadotropin-releasing hormone analog and oxandrolone. J Clin Endocrinol Metab 2006;91:1284-7.

Copyright © 2008 Massachusetts Medical Society.

COLLECTIONS OF ARTICLES ON THE JOURNAL'S WEB SITE

The Journal's Web site (www.nejm.org) sorts published articles into more than 50 distinct clinical collections, which can be used as convenient entry points to clinical content. In each collection, articles are cited in reverse chronological order, with the most recent first.